Paleopathological analysis of a sub-adult Allosaurus fragilis (MOR 693) from the Upper Jurassic Morrison Formation with multiple injuries and infections
by Rebecca Rochelle Laws

A thesis submitted in partial fulfillment of the requirements for the degree of Master of Science in Earth Sciences
Montana State University

Abstract:
A sub-adult Allosaurus fragilis (Museum of the Rockies specimen number 693 or MOR 693; "Big Al") with nineteen abnormal skeletal elements was discovered in 1991 in the Upper Jurassic Morrison Formation in Big Horn County, Wyoming at what became known as the "Big Al" site. This site is 300 meters northeast of the Howe Quarry, excavated in 1934 by Barnum Brown. The opisthotonic position of the allosaur indicated that rigor mortis occurred before burial. Although the skeleton was found within a fluvially-deposited sandstone, the presence of mud chips in the sandstone matrix and virtual completeness of the skeleton showed that the skeleton was not transported very far, if at all. The specific goals of this study are to: 1) provide a complete description and analysis of the abnormal bones of the sub-adult, male, A. fragilis, 2) develop a better understanding of how the bones of this allosaur reacted to infection and trauma, and 3) contribute to the pathological bone database so that future comparative studies are possible, and the hypothesis that certain abnormalities characterize taxa may be evaluated.

The morphology of each of the 19 abnormal bones is described and each disfigurement is classified as to its cause: 5 trauma-induced; 2 infection-induced; 1 trauma- and infection-induced; 4 trauma-induced or aberrant, specific origin unknown; 4 aberrant; and 3 aberrant, specific origin unknown. This study gives a detailed picture of the pathologies of this individual and some of its probable behaviors. The lifestyle and behavior of a carnivorous dinosaur probably predisposed it to injury. "Big Al" is an 87% grown, sub-adult, male, A. fragilis, who may have incurred some injuries during competition with other males and pursuit of prey, and some infection while standing on carcasses, feeding. Additionally, bones exhibiting chronic, localized infection indicate that allosaurs possessed an immune response which allowed them to live with microbial infection in their bones, probably by keeping it localized. This study serves as a basis for future paleopathological analyses. The significance of this allosaur's abnormalities will be better understood once a comprehensive paleopathological study of a large sample of allosaur bones is completed.

PALEOPATHOLOGICAL ANALYSIS OF A SUB-ADULT *ALLOSAURUS FRAGILIS* (MOR 693) FROM THE UPPER JURASSIC MORRISON FORMATION WITH MULTIPLE INJURIES AND INFECTIONS

by

Rebecca Rochelle Laws

A thesis submitted in partial fulfillment
of the requirements for the degree

of

Master of Science

in

Earth Sciences

MONTANA STATE UNIVERSITY-BOZEMAN
Bozeman, Montana

December 1996

APPROVAL

of a thesis submitted by

Rebecca Rochelle Laws

This thesis has been read by each member of the thesis committee and has been found to be satisfactory regarding content, English usage, format, citations, bibliographic style, and consistency, and is ready for submission to the College of Graduate Studies.

John R. Horner John R Horner 12/9/96
(Signature) Date

Approved for the Department of Earth Sciences

W. Andrew Marcus W. Andrew Marcus 12/9/96
(Signature) Date

Approved for the College of Graduate Studies

Robert Brown R L Brown 12/13/96
(Signature) Date

STATEMENT OF PERMISSION TO USE

In presenting this thesis in partial fulfillment of the requirements for a master's degree at Montana State University-Bozeman, I agree that the Library shall make it available to borrowers under rules of the Library.

If I have indicated my intention to copyright this thesis by including a copyright notice page, copying is allowable only for scholarly purposes, consistent with "fair use" as prescribed in the U.S. Copyright Law. Requests for permission for extended quotation from or reproduction of this thesis in whole or in parts may be granted only by the copyright holder.

Signature Rebecca Rachelle Lane

Date 9 DECEMBER 1996

ACKNOWLEDGEMENTS

Funding was provided by Ben and Dorothy Laws, the D.L. Smith Memorial Scholarship, Jack Horner, Museum of the Rockies, Ben and Kathy Laws, a Department of Earth Sciences Teaching Assistantship, and Sigma Xi.

Thanks to all my family members who continually supported me and my quests. David Hanna provided constructive comments and endless moral support. Museum of the Rockies paleontology staff and students gave assistance and answered questions. Special thanks go to Bob Harmon, who first brought some of Big Al's maladies to my attention.

I would also like to give thanks to my committee. Jim Schmitt took the time to carefully edit several drafts of my thesis, and was helpful in the organization of ideas. Susan Gibson assisted with editing, provided me with the necessary histological backround to understand bone microstructure, and made me laugh. Finally, Jack Horner gave me the opportunity and resources to study dinosaur paleopathology, which is what I originally set out to accomplish.

TABLE OF CONTENTS

TABLE OF CONTENTS--Continued

LIST OF FIGURES

ABSTRACT

A sub-adult *Allosaurus fragilis* (Museum of the Rockies specimen number 693 or MOR 693; "Big Al") with nineteen abnormal skeletal elements was discovered in 1991 in the Upper Jurassic Morrison Formation in Big Horn County, Wyoming at what became known as the "Big Al" site. This site is 300 meters northeast of the Howe Quarry, excavated in 1934 by Barnum Brown. The opisthotonic position of the allosaur indicated that rigor mortis occurred before burial. Although the skeleton was found within a fluvially-deposited sandstone, the presence of mud chips in the sandstone matrix and virtual completeness of the skeleton showed that the skeleton was not transported very far, if at all. The specific goals of this study are to: 1) provide a complete description and analysis of the abnormal bones of the sub-adult, male, *A. fragilis*, 2) develop a better understanding of how the bones of this allosaur reacted to infection and trauma, and 3) contribute to the pathological bone database so that future comparative studies are possible, and the hypothesis that certain abnormalities characterize taxa may be evaluated.

The morphology of each of the 19 abnormal bones is described and each disfigurement is classified as to its cause: 5 trauma-induced; 2 infection-induced; 1 trauma- and infection-induced; 4 trauma-induced or aberrant, specific origin unknown; 4 aberrant; and 3 aberrant, specific origin unknown. This study gives a detailed picture of the pathologies of this individual and some of its probable behaviors. The lifestyle and behavior of a carnivorous dinosaur probably predisposed it to injury. "Big Al" is an 87% grown, sub-adult, male, *A. fragilis*, who may have incurred some injuries during competition with other males and pursuit of prey, and some infection while standing on carcasses, feeding. Additionally, bones exhibiting chronic, localized infection indicate that allosaurs possesed an immune response which allowed them to live with microbial infection in their bones, probably by keeping it localized. This study serves as a basis for future paleopathological analyses. The significance of this allosaur's abnormalities will be better understood once a comprehensive paleopathological study of a large sample of allosaur bones is completed.

INTRODUCTION

Purpose

Paleopathology is the study of disease (congenital, infectious, traumatic, toxic, endocrine/metabolic, neoplastic, and systemic disorders) (Mann and Murphy, 1990) in the fossil record. These abnormalities preserved in bone reflect life events because they formed while the animal was alive. Thus, generally speaking, pathological bones can be used to reconstruct lifestyles.

Additionally, certain abnormalities may characterize taxa. If this is true, then frequency of abnormalities and location in the body may be diagnostic of behavior, environment, and physiology. If certain abnormalities do not distinguish taxa from one another, then what are the implications for vertebrates as a whole?

This study gives a detailed picture of the pathological bones in one sub-adult, male, *Allosaurus fragilis* (Museum of the Rockies specimen number 693 or MOR 693; "Big Al") and based on the abnormalities, inferences are made to some of its probable behaviors. In addition, this study serves as a basis for future paleopathological analyses. The significance of this allosaur's abnormalities will be better understood once a comprehensive paleopathological study of a large sample of allosaur bones is completed.

The sub-adult *A. fragilis* (Figure 1) with nineteen abnormal skeletal elements was discovered in 1991 in the Upper Jurassic Morrison Formation in Big Horn County, Wyoming at what became known as the "Big Al" site (Figure 2). Affected bones include five dorsal ribs, cervical vertebra 6, dorsal vertebrae 3, 8, and 13, caudal vertebra 2, chevron 2, gastralia, scapula, manus phalanx I-1, pes phalanx III-1, pes phalanx II-3 (ungal), metatarsal III, metatarsal V, and illium (see Fig. 1). The objective of this study is to describe these bones by comparison of the abnormal elements to normal analogues, and interpret their origin. Pathological abnormalities are also present in some of the theropod bones from the Cleveland-Lloyd dinosaur collection housed predominantly at Brigham Young University (BYU) and the University of Utah (U of Utah) (Petersen et al., 1972; Madsen, 1976); comparisons are made to bones similar in morphology to those of MOR 693. The cause (etiology) of the bone affliction is diagnosed as resulting from trauma, infection, trauma and infection, or aberrancy. The specific goals of this study are to: 1) provide a complete description and analysis of the abnormal bones of the sub-adult, male, *A. fragilis* (MOR 693), 2) develop a better understanding of how the bones of this allosaur reacted to infection and trauma, and 3) contribute to the pathological bone database so that future comparative studies are possible, and the hypothesis that certain

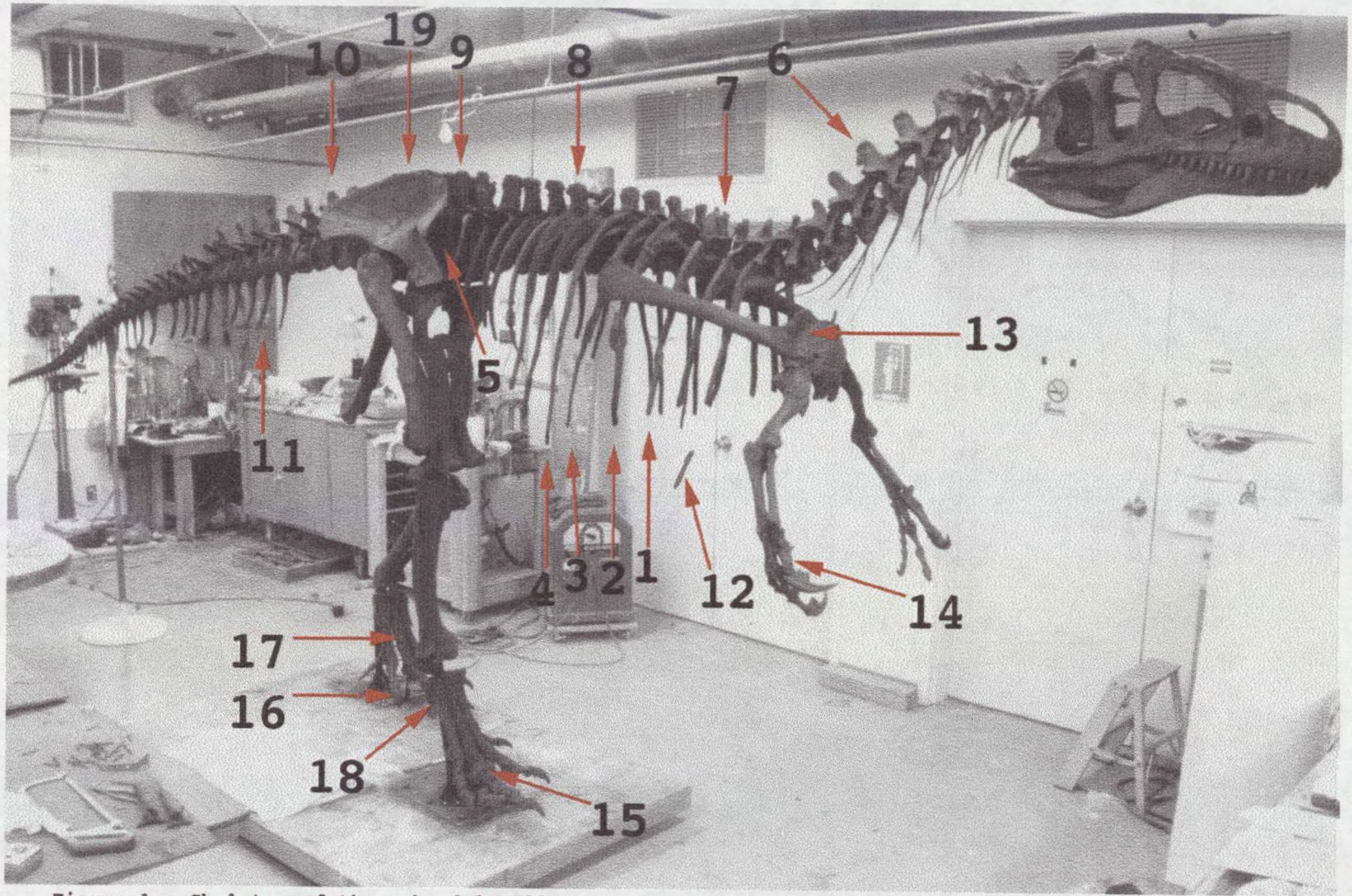

Figure 1: Skeleton of the sub-adult allosaur (MOR 693), "Big Al," from Big Horn County, Wyoming (Copyright Museum of the Rockies, Bruce Selyem photo) showing location of the 19 abnormalities. 1 = dorsal rib 3; 2 = dorsal rib 4; 3 = dorsal rib 5; 4 = dorsal rib 6; 5 = dorsal rib 14; 6 = cervical vertebra 6; 7 = dorsal vertebra 3; 8 = dorsal vertebra 8; 9 = dorsal vertebra 13; 10 = caudal vertebra 2; 11 = chevron 2; 12 = gastralia 5; 13 = scapula; 14 = manus phalanx I-1; 15 = pes phalanx III-1; 16 = pes phalanx II-3 (ungal); 17 = metatarsal III; 18 = metatarsal V; 19 = left illium.

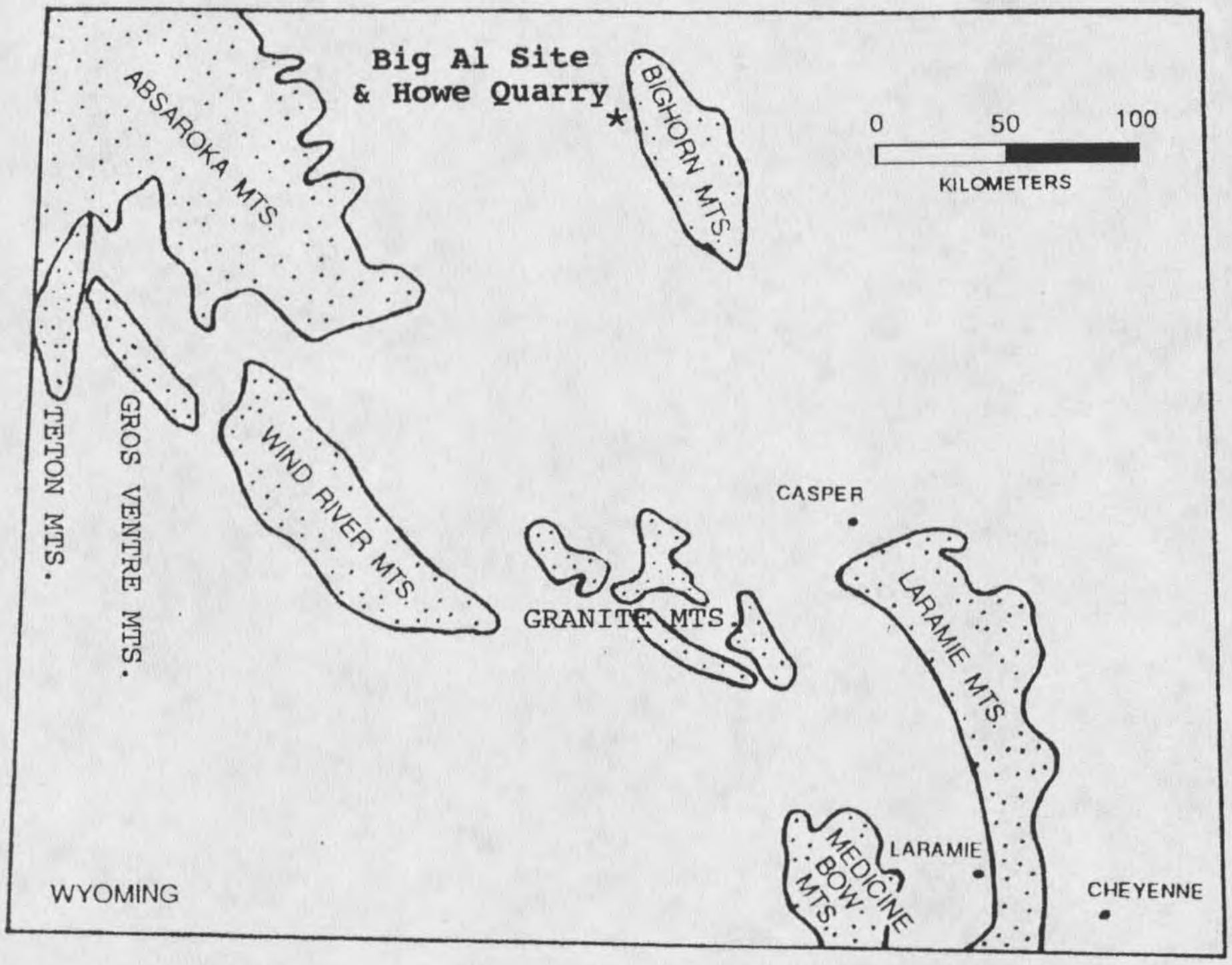

Figure 2: Location map of Big Al site and Howe Quarry in Wyoming (modified from Fiorillo, in press, Fig. 1).

abnormalities characterize taxa may be evaluated. In addition, this analysis provides insight into physiology, behavior, and environmental influences since bone abnormalities record life events.

Although some pathological allosaur bones have been described (Moodie, 1918a; Petersen et al., 1972; Madsen, 1976; Rothschild and Martin, 1993), thorough examination of the frequency of damaged bones has not been done, and thus the occurrence and nature of these abnormalities remains poorly understood. If paleontologists identified, described, and (when possible) interpreted the cause of abnormalities, then a database of the frequency and skeletal distribution of pathologic theropod bones could be compiled. Evaluation of these data would reveal which abnormalities are common for *Allosaurus* and would be useful for future intraspecific comparative studies because the frequency of pathology varied significantly between individuals. Inter-specific comparison of the frequency and anatomical position of pathological bones may show that certain abnormalities characterize taxa and are diagnostic of their lifestyle.

Paleopathology

The term "paleopathology" was first applied by Sir Marc Armand Ruffer in 1910 with respect to his study of ancient Egyptian mummy pathogenesis (Ruffer, 1910; Swinton, 1981).

Ruffer, as well as Elliot-Smith (1908) and Hrdlicka (1914), furthered the science of paleopathology with their studies of the pathologic anatomy of ancient races of man (Moodie, 1918a). The first person to comprehensively search the fossil record for evidence of disease was Dr. Roy L. Moodie, a medical doctor at the University of Illinois in Chicago. Moodie wrote the majority of the early publications in paleopathology in which he describes and interprets a variety of pathological fossils, and is largely responsible for the establishment of the field (see Moodie, 1916a, 1916b, 1917, 1918a, 1918b, 1918c, 1918d, 1918e, 1921a, 1921b, 1922, 1923a, 1923b, 1926a, 1926b, 1927a, 1927b, 1928, and 1930). Moodie (1916a, 1916b, 1918b, 1918c, and 1923a) repeatedly stressed two points: 1) paleontologists should learn to recognize and describe pathological fossil specimens; and 2) medical students interested in the origin of disease and injury should look at the history of pathology as recorded in the fossil record.

Although paleopathology originated in the early part of this century, it was not a major focus of research in paleontology until the early 1980's, when a medical professional (Bruce M. Rothschild) and a vertebrate paleontologist (Larry D. Martin) combined their efforts. Since then, investigations of the bone pathologies of extinct vertebrates have become more frequent (Rothschild and Martin, 1993), although the field is still in its formative years.

The major thrust of paleopathology is to better define the response of bone to disease, and compare these healing strategies to approaches in extant organisms.

Additionally, another emerging goal of paleopathology is to provide insight into things that are not preserved, such as physiology, environmental influences, and behavior. This can be done by identifying the abnormality with respect to its cause (i.e. congenital, infectious, traumatic, toxic, endocrine/metabolic, neoplastic, systemic, or aberrant). For instance, aspects of an individual's physiology may be inferred if that individual was able to withstand a chronic, localized infection (indicated by an infection-induced pathologic bone). Additionally, the presence of infection in a bone gives insight into that individual's environment (i.e. the existence of microbes). Behavioral inferences may be made as with the following hypothetical case: If the cervical vertebra of a sauropod was found to have an exostosis with an allosaur tooth embedded in it (forming a trauma-induced abnormality), then the behavior of that particular allosaur whose tooth was left in the neck of the sauropod may be established. The allosaur was trying to kill the sauropod (evidence supporting predation). The allosaur bit the sauropod on the neck and left a tooth behind, causing bony growth in the sauropod neck vertebra. Using deposition rates observed in living vertebrates (Ortner and Putschar, 1981), the sauropod must have been alive for at least 5-10 days after the event took place in order for significant bone deposition to be preserved. Thus, in this case, correct identification of the potential cause(s) of the abnormality provides insight into physiology, environmental influences, and behavior.

Other Exceptional Dinosaur Localities in the Morrison Formation

This study provides a model for future paleopathological analyses of the Morrison Formation dinosaur fauna. In the Brushy Basin Member of the Upper Morrison Formation, exceptional preservation of dinosaurs occurs at the Cleveland-Lloyd Quarry, Dinosaur National Monument (National Park Service quarry building), and Howe Quarry. If paleopathological studies were done on the dinosaur material from these sites, then a database would be available for comparative study. Additionally, a study of inter-specific variation of the frequency and anatomical location of abnormalities would be possible and may reveal that certain pathological ailments characterize taxa and reflect their lifestyle.

At the Cleveland-Lloyd quarry near Price, Utah, a minimum number of 44 *A. fragilis* of different size are represented by disarticulated elements. Also represented at the site are *Camptosaurus*, *Stegosaurus*, *Camarasaurus*, *Apatosaurus*, *Ceratosaurus*, *Stokeosaurus*, and *Marshosaurus*. This site is unusual because carnivorous dinosaur remains account for 75%

of the assemblage. The bones are in (Madsen, 1976, p. 5) "...poorly stratified, bentonitic, calcareous and siliceous shales that are overlain by a dense, hard, tuffaceous, freshwater limestone." Some skeletal elements exhibit green stick fractures which only occur while bone is fresh (i.e. not fossilized). More than 10,000 bones were removed at this site (Madsen, 1976). The *A. fragilis* material has been utilized for studies of anthropometry (Smith, 1996) and histology (growth series) (Bybee, 1996). Additionally, a preliminary pathological analysis has been done by Petersen et al. (1972) on the abnormalities in the Cleveland-Lloyd dinosaur collection.

The quarry in the National Park Service building at Dinosaur National Monument (Jensen, Utah) occurs in a fluvial sandstone, interpreted as a braided river channel deposit (Lawton, 1977; Dodson et al., 1980). More than 1,000 bones have been exposed representing *Camarasaurus*, *Apatosaurus*, *Diplodocus*, *Allosaurus*, *Stegosaurus*, and less frequently, *Barasaurus*, *Ceratosaurus*, *Camptosaurus*, and *Dryosaurus* (Dodson et al., 1980). In her taphonomic study of the accumulation, Lawton (1977, p. 125) stated that "[t]he presence of several depositional phases and horizons in which bones exposed subaerially were deposited with fresh carcasses..." is reminiscent of attritional rather than catastrophic accumulation.

The Howe Quarry (Figure 3), located approximately 300 m

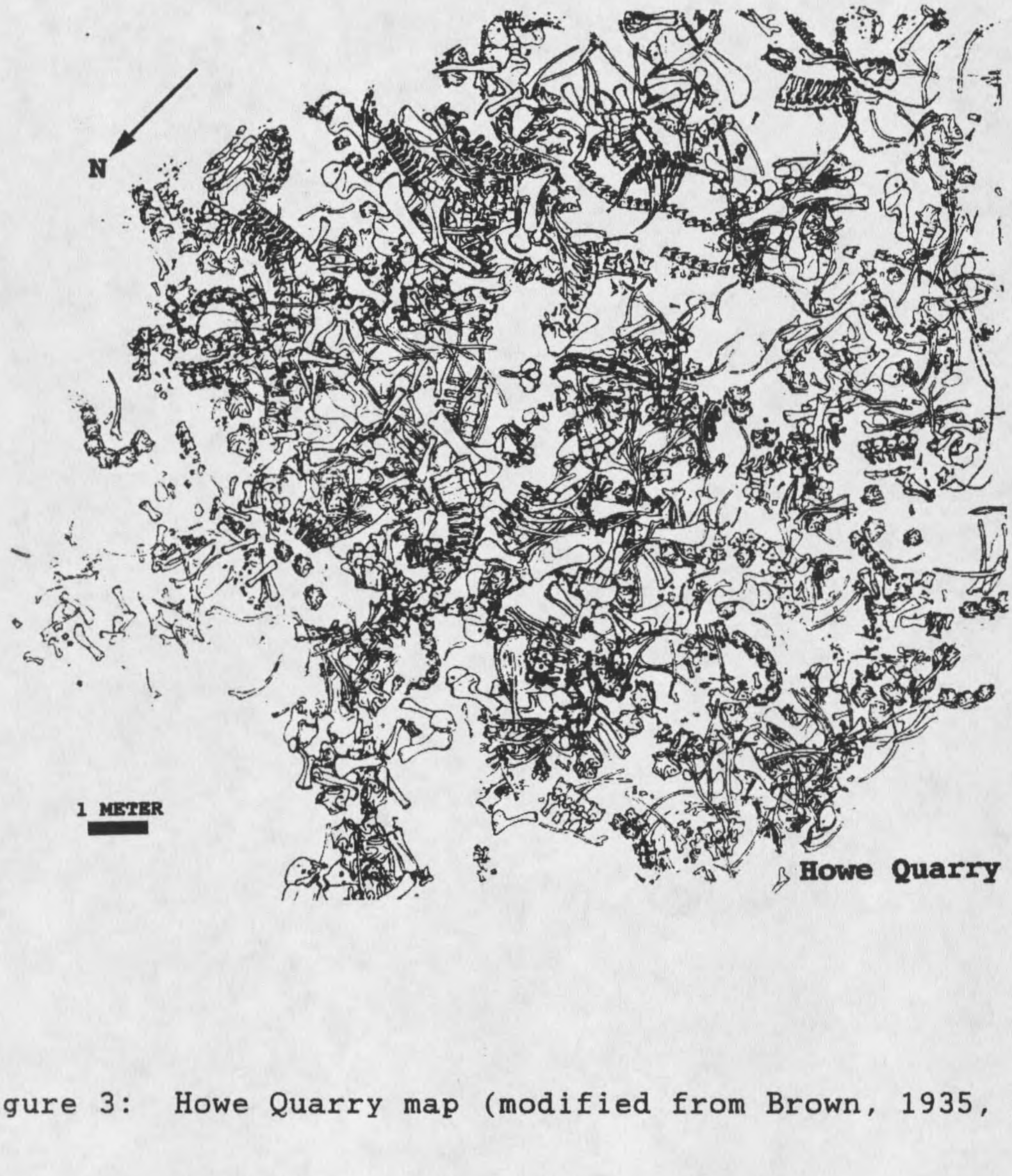

Figure 3: Howe Quarry map (modified from Brown, 1935, p.6).

SW from the "Big Al" site (see Fig. 4), was excavated in 1934 by Barnum Brown of the American Museum (New York) during the Sinclair Expedition (June 1 - November 17). Taxa represented by 4,000 frequently articulated bones (at least 20 individuals), include *Barasaurus*, *Morosaurus*, *Camptosaurus*, *Apatosaurus*, and *Diplodocus*. *Allosaurus* is represented only by 12 teeth (Brown, 1935). The bones occur in a 60 cm (2 feet) thick siltstone which is underlain by a light tan, fine-grained, subrounded, well-sorted, quartzarenite. The contact between the siltstone and quartzarenite is sharp. The sandstone is horizontally stratified and exhibits soft sediment deformation. The bone layer, is thickest in the central portion where elements are stacked two and three deep, and thins at its outer edges. Additionally, twelve articulated sauropod legs and feet were preserved standing upright, in life position (Brown, 1935). The presence of the elements in such a fine-grained matrix, geometry of the bone layer, occurrence of articulated vertebral columns with pelvic/shoulder girdles and skin impressions, soft sediment deformation of the underlying sandstone, and twelve articulated upright legs and feet indicates that the dinosaurs died in this quiet, low-energy, floodplain environment and were not transported. No complete skulls were ever found at this site, only a few cranial fragments and peg-like teeth.

METHODS

Geologic Data Collection Procedures

Two stratigraphic sections were measured using a Jacob's staff and Brunton compass. Measured section 1 (Plate 1) is located 10 m southwest of the "Big Al" site (see Figure 4), and measured section 2 (Plate 1) is 50 m northeast of the site. Lithologic description of the rocks followed guidelines set by Rogers (1994). Paleocurrent measurements were taken on trough cross-bedding with good three-dimensional exposure in outcrops adjacent and laterally equivalent to the site. Lithofacies were designated using Miall's (1978, 1985) classification system and facies codes. Depositional environment was interpreted by analyzing the combination of architectural elements present at the site (Miall, 1985).

Taphonomic Data Collection Procedures

The skeleton of MOR 693 was collected in September, 1991. I was not present during excavation, and consequently did not personally collect the taphonomic data which can only be recorded while the bones are still in the ground (i.e. trend, plunge, etc...). The field map of the quarry made by Bob Harmon (Chief Preparator, Museum of the Rockies) was subsequently re-drafted by Brent Breithaupt (Director of the Geological Museum, Laramie, Wyoming). Thus, my interpretations of the taphonomy of the "Big Al" site are based on my measured sections, my observations of sedimentary structures and lithology of the bone producing layer, my evaluation of bone preservation, and the quarry map.

Paleopathological Analysis Procedures

The 19 abnormal elements were analyzed in macroscopic view, five were thin-sectioned, and two were studied as 3-dimensional computer images derived from overlapping Computerized Axial Tomography (CAT) scans. Initially, the entire skeleton of MOR 693 was examined. Bones thought to be abnormal were compared to normal *A. fragilis* analogues. Comparison to normal bones aided in differentiation between abnormal bone structure and normal morphologic variation. The next step was a careful description with respect to the location, extent, and texture of the abnormal area. After describing the macroscopic appearance of the bone, it was possible to classify the abnormality, in this case as trauma-induced, infection-induced, trauma- and infection-induced, or aberrant.

A three-dimensional computer image of two bones was obtained by overlapping CAT scans (scanning done in the CAT Department at the Bozeman Deaconess Hospital; 3-D image generated with medical software and Sun computer). The bone was placed in a plastic bag, wrapped in damp cotton towels, and situated on the padded table over which the scanner moves. The resulting computer image allowed sectioning of the bone on the screen and showed areas of different density, revealing bone structure. Secondary bone (zonal lamellar), present in normal areas, was more dense than the primary bone (fibrolamellar) which was laid down by osteoblasts in abnormal areas. The image allowed an examination of the extent of primary versus secondary bone, which aids in the classification. This technique is limited, however, in that the image resolution is not detailed enough to reveal the microscopic morphology within the pathologic bone. Thus, in order to analyze the microscopic nature of the abnormal areas, thin-sectioning of the element was required in a few cases.

Since thin-sectioning destroys bone, the bone was molded, cast, photographed, and drawn before it was thin-sectioned. The piece of bone was embedded in Silmar (plastic). After the liquid plastic was poured around the bone, it was repeatedly placed in a vacuum (VWR Scientific vacuum 1410) in order to remove bubbles. The specimen was then refrigerated overnight. Thin-sections were cut on a Beuhler Isomet low speed saw with a diamond-coated blade. The section was then glued with 2-ton epoxy to a glass slide and ground by hand on a Beuhler Ecomet II grinder/polisher, using progressively finer sandpaper (grit range = 60-4,000). Slides were polished on the Beuhler Ecomet

II with an aluminum oxide powder. Thin-sections were viewed under a light microscope (Leitz Laborlux II Pol S) with polarized and non-polarized light. More detailed examination of the section was done with a scanning electron microscope (SEM housed in the Department of Physics, Montana State University-Bozeman), whereby Energy Dispersive X-ray Spectrometry was utilized in elemental analyses. Slides were coated with carbon in preparation for elemental analyses, and gold-palladium otherwise.

STRATIGRAPHIC SETTING

In 1991, the sub-adult *A. fragilis* was found by the commercial fossil firm of Siber and Siber 300 m northeast of the Howe Quarry in the Brushy Basin Member of the Upper Jurassic Morrison Formation of north-central Wyoming (Figure 4). The site is on Bureau of Land Management administered land west of the Big Horn Mountains (sec. 9, T 54 N, R 91 W, Big Horn County, Wyoming). Nearly 95% of the skeleton was preserved, making this one of the most complete allosaurs ever found. The completeness estimate includes portions of the tail section which were destroyed with a backhoe employed by Siber and Siber during excavation of the hillside just below the skeleton.

The "Big Al" site and Howe Quarry are located in the upper 37 m of the Brushy Basin Member, and the stratigraphic unit containing the Howe Quarry has been dated as ~145.7 Ma, occurring in the magnetic chronozone M20 (Swierc and Johnson, 1996). The contact here with the Lower Cretaceous Cloverly Formation is tentatively placed at the base of a 2 m thick laterally continuous pink-weathering sandstone (Plate 1). The allosaur skeleton was found in a 6 m thick channel sandstone which is traceable over an area of 0.8 square km (0.5 square mi) and located stratigraphically just above the level of the Howe Quarry (see Fig. 4). This sandstone, a buff-colored,

Figure 4: Photo, looking west, showing lateral and vertical relationships of the Howe Quarry, measured section 1 (MS 1), and Big Al site.

fine-grained, subrounded, well-sorted, quartzarenite, is overlain by a dark green mudstone. Iron nodules are present in the sandstone and stain the surrounding rock reddish-orange; the nodules have a size range of 0.2-18 cm. Also present are distinct layers of matrix-supported, mud-chip conglomerate bounded by erosional scours. The greenish-gray siltstone clasts are subangular. The matrix surrounding the bones of MOR 693 contains some mud chips, as well as carbonized plant material. No invertebrate fossils were found with the skeleton. No trace fossils were observed in the quarry floor or walls.

Sandstone Facies

Two dominant sedimentary structures are present in this facies: trough cross-bedding and horizontally stratified beds and laminations. Paleocurrent measurements on trough cross-bedding indicated that paleoflow direction was between 210 and 240 degrees, with a mean of 210 degrees (Figure 5). The sandstone was not exposed to the NW, but was traced laterally for 800 m to the SE, where the exposure had been eroded. The thickness of the sandstone is 6 m at the quarry; it thins to approximately 2 m at the SE exposure.

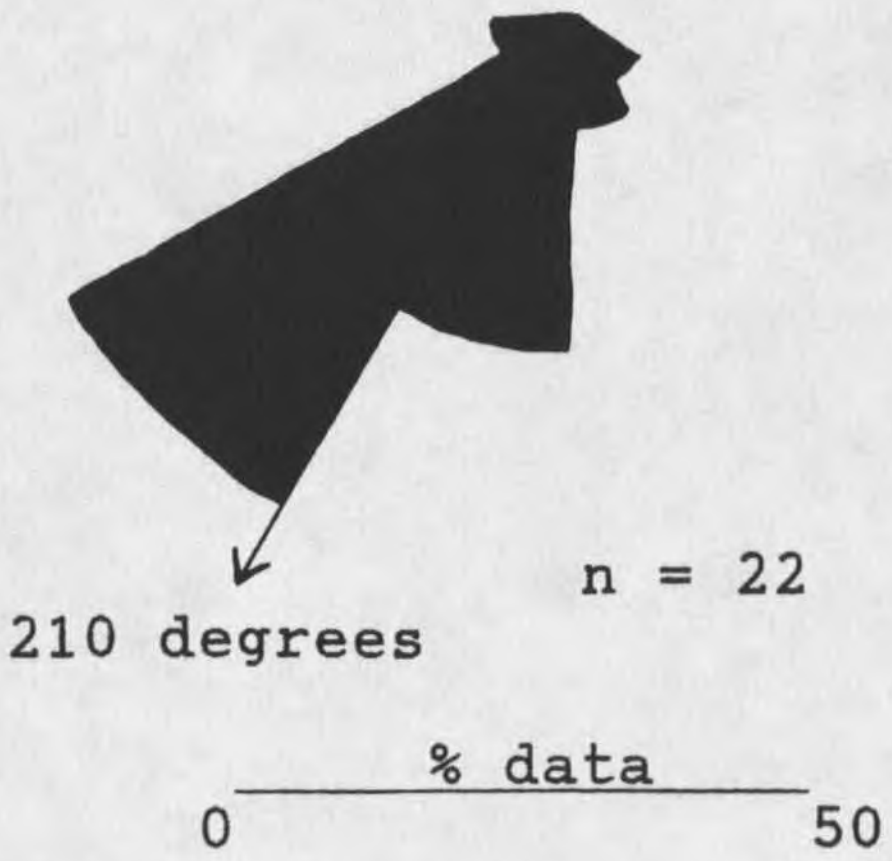

Figure 5: Rose diagram of paleoflow data from trough cross-bedded channel sandstone at base of measured sections (Plates 1 and 2).

Trough cross-bedded sandstone lithofacies (St)

The lower 5.6 m of the sandstone facies is an orange-weathering, light tan, subrounded, well-sorted, calcite-cemented, fine-grained quartzarenite with an erosional contact at the base. Mud chips and carbonized plant material are abundant at the base, decrease in frequency upward, and when present occur along bedding planes. Medium-scale trough cross-bedding is present throughout the unit. "Big Al" was found in the upper meter of the sandstone unit (between 4.6 and 5.6 m up from the erosional base) and sauropod material representing several individuals, collectively called "Big Horn Thunder Lizard" (BHTL), was found stratigraphically below MOR 693.

Horizontally stratified sandstone lithofacies (Sh)

The uppermost 40 cm of the sandstone unit is a brown-weathering, light tan, subrounded, well-sorted, calcite-cemented, very fine- to fine-grained quartzarenite with a sharp contact with the underlying trough cross-bedded sandstone. Two to 5 cm-thick horizontal beds present in the lower 20 cm grade into 1-2 cm thick horizontal laminations above.

Mudrock Facies

Mudrock facies comprise siltstone, mudstone, and claystone which are green, red, brown, and pink in color. Bounding surfaces are always gradational, except when overlain by trough cross-bedded sandstone facies. Thicknesses range from 20 to 800 cm.

DEPOSITIONAL ENVIRONMENT

The vertical profile and overall fining upward sequence present in and adjacent to the "Big Al" quarry are similar to the classic point bar sequences and fluvial (meandering river) environments of deposition as described by Jackson (1976), Friend (1983), Nanson and Page (1983), and Bridge (1985). However, Miall (1985, p. 261) has demonstrated that the traditional utilization of vertical profiles for facies determination is inadequate because "...three-dimensional variations in composition and geometry..." are ignored. Additionally, Miall's classification is inherently better than previous systems because it is based on descriptive characters. Architectural-element analysis after Miall (1985) shows that three of eight architectural elements are present at the "Big Al" site: "sand bedforms" (SB), "overbank fines" (OF), and "laminated sand" (LS). Based on different combinations of these architectural elements, two models are favored: Model numbers 8 and 11 (Miall, 1985, p. 288). Model 8 (SB, OF, and minor "lateral accretion" (LA)), composed of sand and fines, is diagnostic of a "low-to-high-sinuosity, stable, anastomosed channel system" (Miall, 1985, p. 294). Model 11 (SB, (OF)), composed of sand and minor fines, "...typifies distal braidplains, particularly in arid regions where ephemeral run-off forms a network of shallow, interlacing, poorly defined channels" (Miall, 1985, p. 295-297). Thus, as is shown by the two models which best fit the lithofacies and architectural elements present at the "Big Al" site, the river system at this location could have been either anastomosed or braided. This is consistent with previous depostitional environment interpretations for the Brushy Basin Member of the Morrison Formation elsewhere in the U.S. (Dodson et al., 1980; Peterson and Turner-Peterson, 1987; Turner and Fishman, 1991; Cooley, 1993; Fiorillo, 1994).

MOR 693 and BHTL were buried by sand in an anastomosed or braided river after dying either on the floodplain near the channel and falling in during bank collapse, or in the channel. The opisthotonic position of "Big Al" indicated that the carcass remained unburied long enough for rigor mortis to arch the head and tail dorsally. Although the skeleton was found within a fluvially-deposited sandstone, the presence of mud chips in the sandstone matrix (Smith, 1972) and virtual completeness of the skeleton show that the skeleton was not transported very far (Shipman, 1981), if at all. Additionally, the presence of lower flow regime sand dunes (St) in the channel containing "Big Al" indicate burial by a current with low flow velocity. Thus, "Big Al" was buried in a river channel very near to where the allosaur expired after some disarticulation occurred due to either water current action or bloating (see Taphonomy section).

TAPHOMONY

The 95% complete skeleton of MOR 693 consists of articulated and associated elements (Figure 6). The left skeletal elements of MOR 693 are better preserved than those of the right side, probably because the allosaur was found laying on its left side, exposing the right side. The skeleton was oriented in an opisthotonic position, with the head and tail arched towards one another dorsally. Decay and subsequent contraction of the ligaments and tendons along the length of the spine due to rigor mortis caused the skeleton to be contorted into this position. No signs of macro-scavenging (i.e. tooth marks from gnawing) are present on the bones. The completeness of the skeleton, preservation of a pterosaur bone fragment (cortical bone was extremely thin), and presence of mud-chips (Smith, 1972) suggest very little transport.

The skull, vertebral column, left illium, femur, tibia, fibula, metatarsals, and pes phalanges were found laying in articulation. However, some of the rib cage was disarticulated and the right leg was found on the dorsal side of the animal, along its back. The location of right leg and foot bones with respect to the body is coincident with paleocurrent direction. The articulation of the left side of the body indicates that it was probably partially buried in the sediment. Partial burial would have anchored the carcass

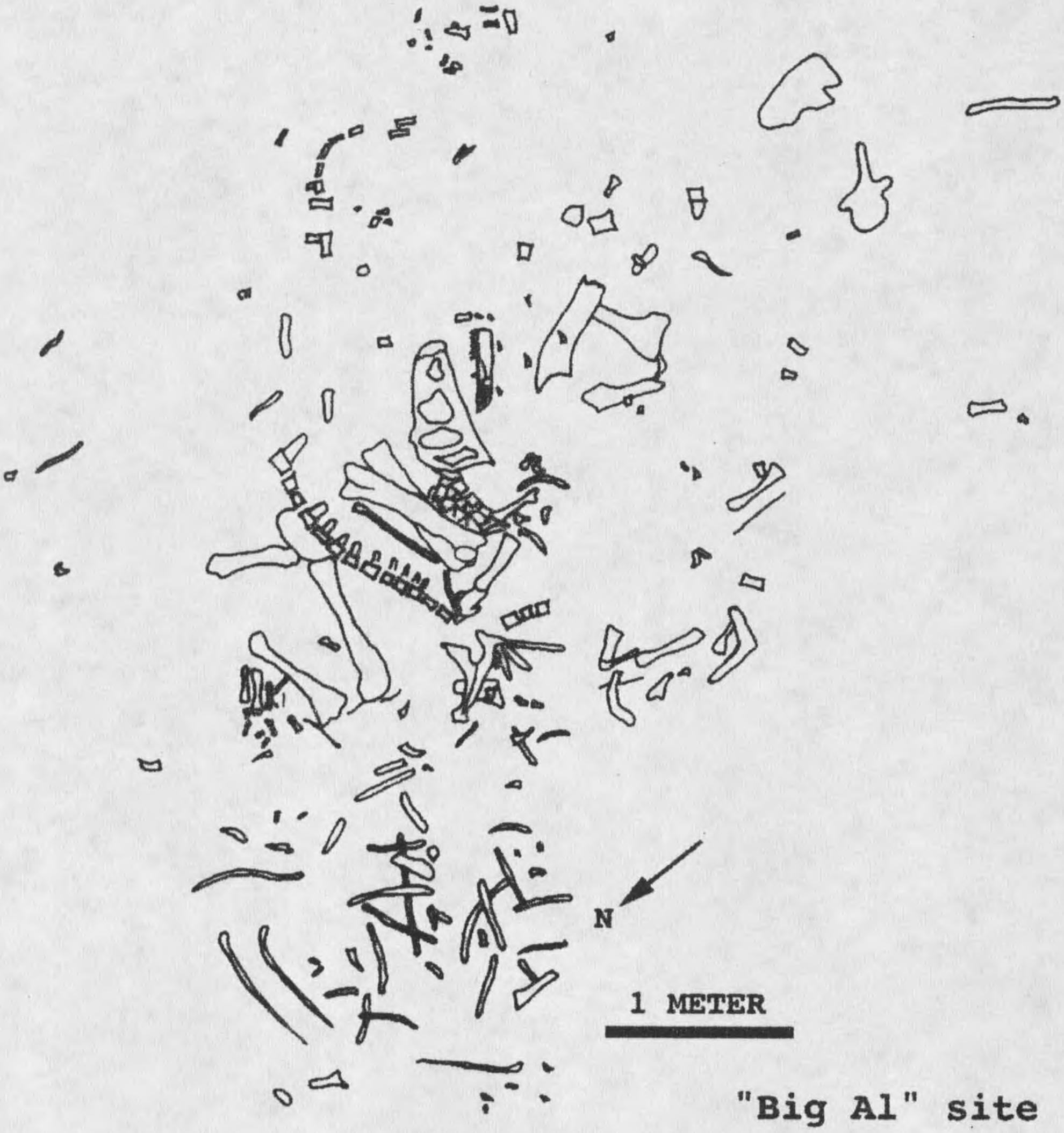

Figure 6: MOR 693 quarry map re-drawn from Bob Harmon's original map by Brent Breihaupt.

in the channel, protecting that part of the skeleton from disarticulation and preventing transport during the bloating caused by decay. Two scenarios are envisioned which would allow disarticulation of the abdominal region and dislocation of the right leg before burial: 1) if the soft tissue was partially removed from the abdomen, then water current could have disarticulated the rib cage or, 2) the carcass bloated as gases built up in the body during decay and then exploded. As the animal was laying on its left side, bloating would have elevated the right leg. Explosion of the bloated animal may have disarticulated the rib cage, and caused the elevated right leg to be flipped over the animal along its back.

Also in the quarry, stratigraphically below "Big Al," the remains of several articulated and associated sauropod dinosaurs of various sizes (BHTL) and a pterosaur bone fragment were found. Because the depositional environment was fluvial, it is likely that BHTL and "Big Al" are spatially and temporally mixed. Thus, it is dangerous to assume that these animals lived together in the same geographic area or that they died in the environment in which they lived (Shipman, 1981).

RESULTS OF PALEOPATHOLOGICAL ANALYSIS

The 19 abnormal bones of MOR 693 (described in Appendix and shown in Fig. 1) are classified as either trauma-induced, infection-induced, trauma- and infection-induced, or aberrant. The five elements affected by trauma include right dorsal ribs 3, 4, and 5, chevron 2, and left gastralia. Right pes phalanx III-1 and right metatarsal V are infection-induced. The abnormality present on right manus phalanx I-1 is trauma- and infection-induced. Right dorsal rib 14, right scapula, left metatarsal III, and left pes ungal II-3 are either trauma-induced or aberrant, specific origin unknown. The bone growth projecting off neural spines of cervical vertebra 6, dorsal vertebrae 8 and 13, and caudal vertebra 2 is aberrant and is due to ossification of the inter-spinous ligament. The origin of the aberrant spicule, exostosis, and thickening observed on dorsal rib 6, dorsal vertebra 3, and left illium, respectively, is unknown. Examples of pathologic allosaur bones from the Cleveland-Lloyd (C-L) collection (BYU and U of Utah) that are similar in morphology to those of MOR 693 are referred to where applicable.

In most cases, careful observation and description of the location, extent, and texture of abnormal bone, makes it possible to classify abnormalities as trauma-induced, infection-induced, or both, and hence infer the mechanism responsible for the disfigurement. If classification into one of these categories is not possible, then the abnormality is termed aberrant. For instance, a rib with a transverse fracture united by a callus is easily identified by its morphology. However, it is not always possible to determine the cause of other abnormalities because the diagnosis is constrained by the nature of bone cell response--bone cells are able to either produce or destroy bone, and the resulting morphology is therefore some combination of the two processes. Chaplin (1971) observed that a specific abnormal morphology can be caused by different diseases. Even though etiologic identification of an abnormality is only achieved in some cases, it is possible to recognize aberrancy by comparison of the observed morphology to normal analogues. Therefore, a classification scheme based on descriptions of abnormal bone morphology is useful for differentiation of trauma, infection, and aberrancy.

Trauma-induced pathologies are characterized by a bony growth called a callus, the osseous (bony) material woven between ends of a fractured bone that is ultimately replaced by secondary bone in the healing process. In most cases, the callus surrounds the perimeter of the bone, is localized, and usually has a different texture in comparison to normal segments of the bone. Fractures can be caused by five different types of stress (tension, compression, twisting, bending, and shearing) and divided into direct and indirect violence (Ortner and Putschar, 1981; Mann and Murphy, 1990).

Infection-induced abnormalities are indicated by the presence of an exostosis, a bony growth that arises from the surface of a bone. Channels and openings that lead into the bone may or may not be present. The channels and openings are caused by abscess formation, where disintegration and displacement of tissue results in localized collection of pus. In later stages of infection, the exostosis (involucrum) surrounds and causes necrosis of the original bone (sequestrum) (Ortner and Putschar, 1981).

Due to the limited nature of bone cell response, the origin of some abnormalities remains unknown. If etiologic identification was not possible after description of the location, extent, and texture of the abnormality and comparison to normal and abnormal examples, then the abnormality was classified as aberrant.

Dorsal ribs

Dorsal ribs 3, 4 (Figure 7), and 5 possess trauma-induced, healed, malaligned fractures with callus formation, resulting from direct violence to the right side of Big Al. Healed fractures are also present on ribs (UUVP 4946, 10,284, and 2753 at BYU; UUVP 5661 and 5660 at U of Utah) in the C-L collection. A three-dimensional CAT scan image of dorsal rib 4 (Figure 8) reveals the extent of primary bone which formed

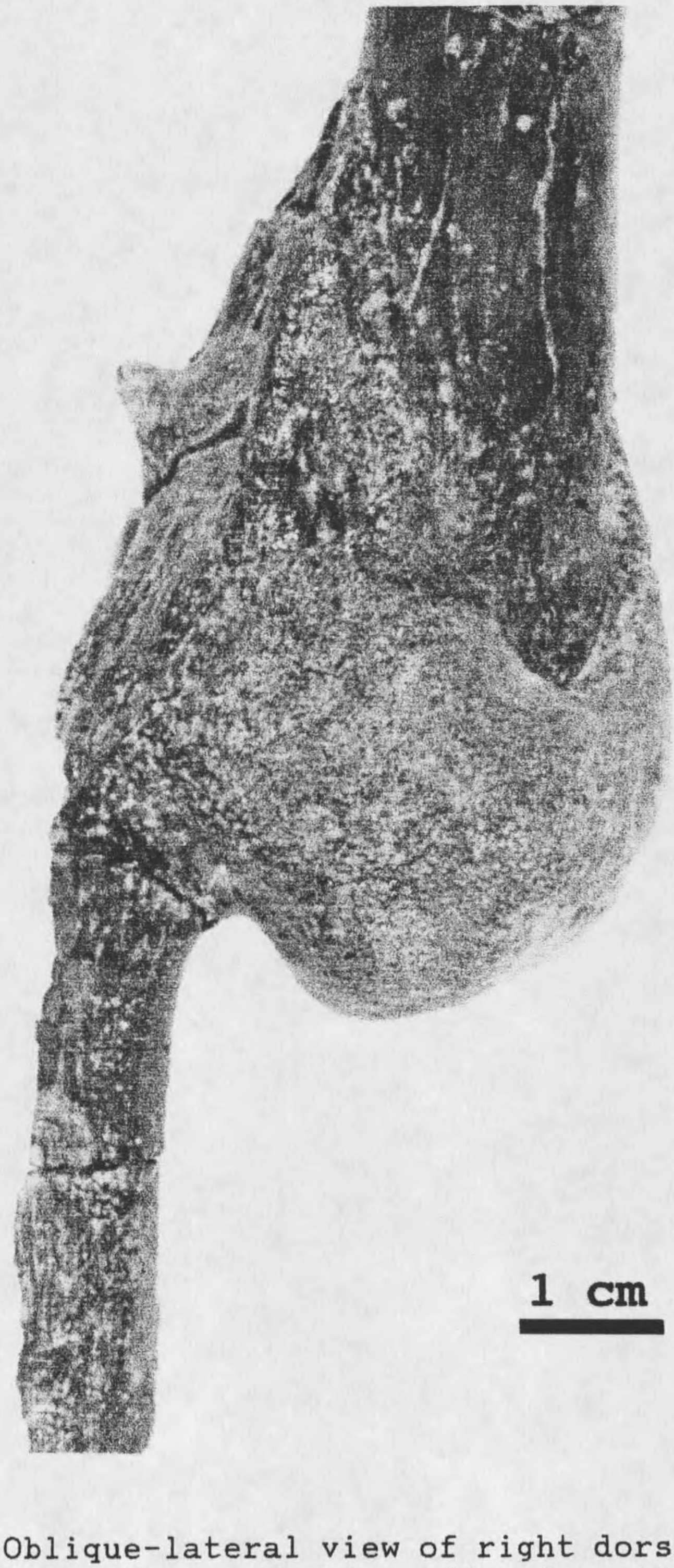

Figure 7: Oblique-lateral view of right dorsal rib 4 showing a malaligned fracture united by callus formation (photo, Terry Panasuk; Copyright Museum of the Rockies). For anatomical location of rib see Fig. 1.

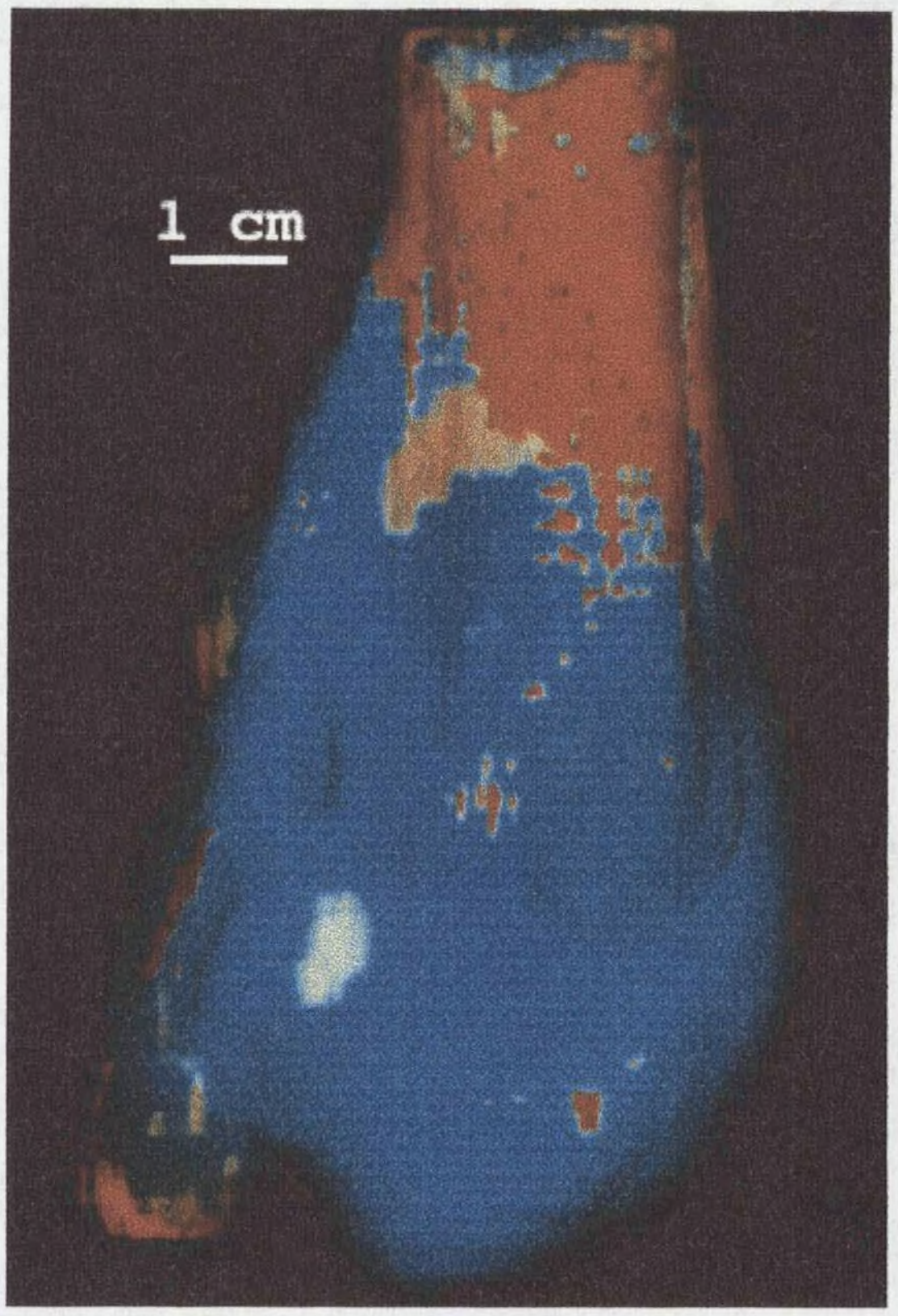

Figure 8: Computer-generated three-dimensional CAT scan image of dorsal rib 4 in Figure 7 reveals the extent of primary bone which formed in response to the fracture event because primary and secondary bone have different densities. Blue areas are coincident with the callus that reunited the original rib segments (red areas).

in response to the fracture event, because primary and secondary bone have different densities.

Dorsal rib 6 does not have the appearance of a healed fracture. Although the spicule of bone projecting off the shaft could have originated during development, the actual origin of the aberrant spicule is unknown.

The displaced bone spicules on the shaft of dorsal rib 14 are due to an incomplete fracture (trauma-induced) or developmental growth disturbance (aberrant).

Vertebrae

The origin of the aberrant exostosis on the anterior portion of the left side of the centrum of dorsal vertebra 3 is unknown. Trauma-induced etiology due to displacement of left dorsal rib 3 ventrally is ruled out because paraspinal muscles would not have allowed displacement of the rib. Similar growth is present on two distal caudal vertebrae in the C-L collection (U of Utah). Aberrant rough exostoses and small lesions occur on the anterior half of the ventral surface of the centrum (UUVP 5659) and the lateral and ventral surfaces of the centrum (UUVP 5658).

Cervical vertebra 6, dorsal vertebra 8, and caudal vertebra 2 all have aberrant bony growth extending posteriorly from their neural spines; dorsal vertebra 13 has aberrant bone extending anteriorly from its neural spine. Trauma-induced avulsion of part of the neural spine growth center may have caused growth to occur outward from the process. However, these vertebrae are widely spaced in the body, implying a separate traumatic event for each element. Another possibility is that these aberrancies resulted from ossification in the interspinous ligament which connects the neural spines (Mann and Murphy, 1990). The latter explanation is favored because it is simpler and more parsimonious than the first.

Chevron

The bulge on the left diaphysis of chevron 2 is a trauma-induced feature caused by direct violence to the proximal tail. The bone received a transverse fracture and healed. The callus, visible as a slight bulge, is extensively remodeled as shown by its small size and smooth texture. Because remodelling of bony tissue takes time, it is inferred that the injury occurred between 6 months and 1-2 years before the allosaur's death. Petersen et al. (1972) identified an extensively remodelled callus on the mid-diaphysis of a large allosaur humerus (UUVP 3435, BYU), representing an "old" injury where the callus had been almost completely resorbed.

Gastralia

A segment of left gastralia 5 received a trauma-induced fracture, resulting from direct violence to the abdominal region. The gastralia was fractured transversely, and healed in alignment with callus formation.

Scapula

The hole on the lateral-dorsal blade of the right scapula is trauma-induced or aberrant. Two scapula (UUVP 1528 and 5599) in the C-L collection at BYU have lesions surrounded by a lip of bone on their lateral blades. Petersen et al. (1972, p. 46) state that the cause of the features on UUVP 1528 and UUVP 5599 may have been osteomyelitis: "[a]s the infection spreads inward, an abscess of dead bone is formed, which is later encircled by new bone." It would be very speculative to say that the hole on the blade of MOR 693's scapula is the result of early infection as the infection would have been only a couple days old at the time of death (Pete Wendt, pers. comm., 1996). Thus, comparison to the C-L scapula is not warranted. The origin of the hole on the scapula of MOR 693 is due to shoulder region trauma or aberrancy (i.e. an extra foramen).

Phalanges

Manus phalanx I-1

The entire shaft of right manus phalanx I-1 is surrounded by bone growth and rough in texture (Figure 9). A cross-sectional thin-section viewed with a SEM reveals a fracture line through the cortex (Figure 10) indicating that the first digit in the right hand was twisted such that phalanx I-1 was fractured obliquely and longitudinally. However, a callus forming in response to such a fracture would have been much more conservative as little displacement occurs with lengthwise fractures. The rough, irregular texture and extent of the bone growth are more reminiscent of osteomyelitis (Wendt, pers. comm., 1996). Thus, the morphology of the phalanx is not only trauma-induced, but also infection-induced. It is impossible to determine when the fracture occurred in relation to the osteomyelitis.

Osteomyelitis originates from trauma or blood-born infection (Mann and Murphy, 1990). If trauma-induced, then the fracture must have been open to the outer environment in order for the microbe to enter. This origin is unlikely because offset of oblique-longitudinal fractures is difficult. If the infection was blood-born, then it would have arisen in the inter-medullary space. First, pus would be produced in the marrow cavity. Then the infective organism could have



Figure 9: Lateral view of right manus phalanx I-1 showing irregular, rugose, growth on the outer surface (photo, Terry Panasuk; Copyright Museum of the Rockies). Anterior view of allosaur hand (modified from Madsen, 1976) at upper left shows anatomical location of phalanx. Location of Figure 10 cross-section (x-sec) shown. Scale for pathological phalanx only.



Figure 10: Cross-section, viewed with SEM, of manus phalanx I-1 through the cortical bone. Opaque area between arrows is primary bone which infilled the oblique-longitudinal fracture through the secondary bone of the cortex.

escaped from the inter-medullary space through a blood vessel opening, or a weak area in the bone such as the fracture. Next, pus began to form underneath the periosteum, the outer tissue covering on bone, elevating it. The periosteum still had an adequate blood supply and sub-periosteal bone deposition in the form of an exostosis began. The exostosis cut off blood supply to the original bone, resulting in necrosis. The original bone, now necrotic, is a sequestrum and the exostosis around the outside is an involucrum. Drainage canals, channels, and lesions are not required in infective processes if the infection and pus are contained in the bone (Wendt, pers. comm., 1996). Thus, manus phalanx I-1 was fractured longitudinally and infected by osteomyelitis.

Pes phalanx III-1

The exostosis and lesion on right pes phalanx III-1 (Figure 11) are infection-induced. If a microbe originated in the inter-medullary space of the phalanx, then the exostosis formed by the same process described for the manus phalanx (osteomyelitis), with the proximal joint surface lesion functioning as a route for pus drainage. Another possibility is that the lesion on the proximal surface was caused by joint infection, because joints are good locations for microbial entrance (Swanson, pers. comm., 1995; Wendt, pers. comm., 1996). If the microbe entered the joint between metatarsal III and phalanx III-1, then subsequent invasion through the

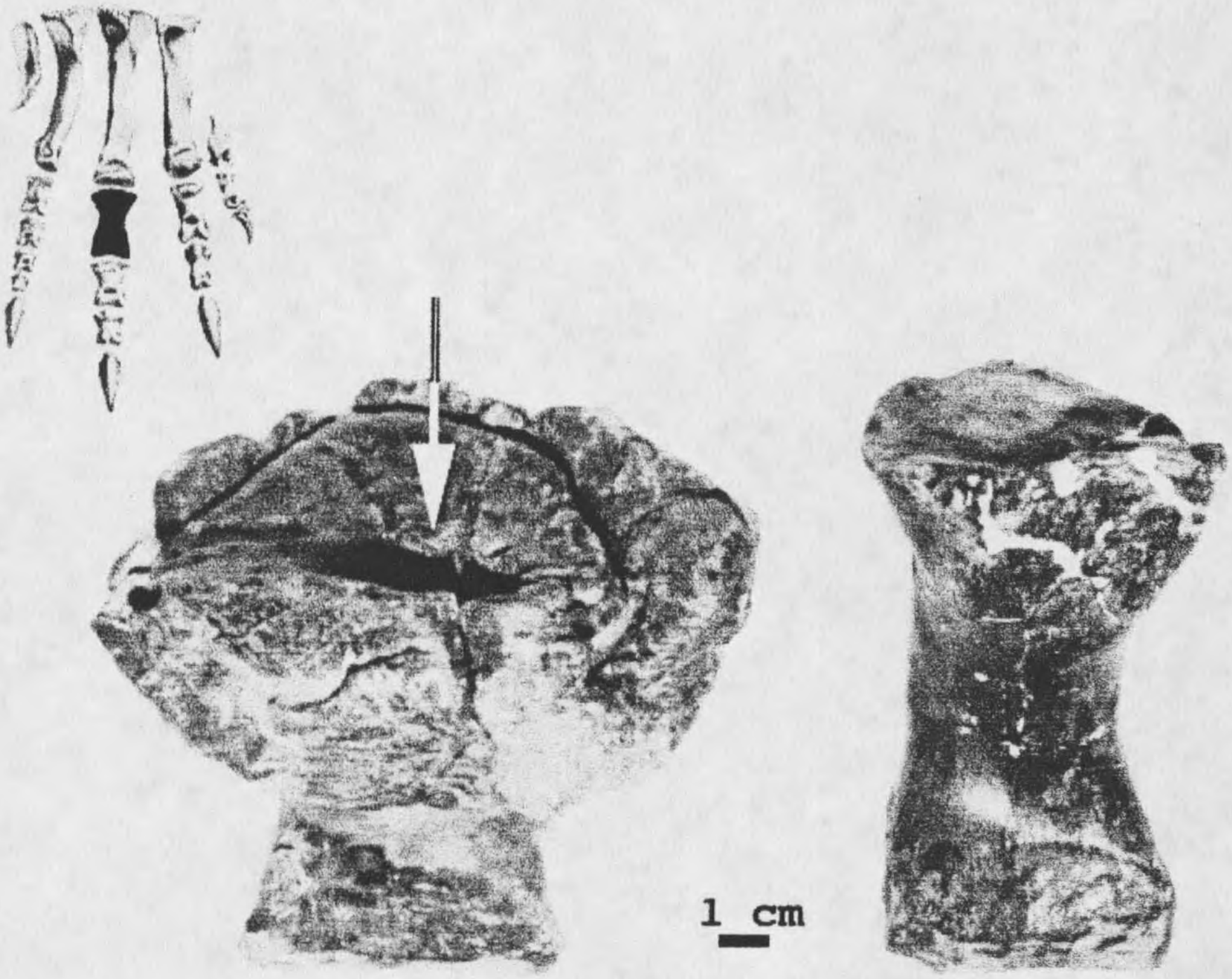

Figure 11: Inferior view of pathological right pes phalanx III-1 (left) and normal left pes phalanx III-1 (right) from MOR 693 (Copyright Museum of the Rockies). Anterior view of allosaur foot (modified from Madsen, 1976) at upper left shows anatomical location of pathological phalanx. Scale applies to phalanges in foreground only. Note large exostosis surrounding the proximal portion of phalanx on left, and lesion on proximal articulation surface (arrow).

infection-induced lesion into the phalanx would have resulted in osteomyelitis, and thus, the exostosis (involucrum). Regardless of the microbial pathway, the phalanx was affected by osteomyelitis. The infection was localized to pes phalanx III-1 as no lesions or exostoses are present on the adjacent bones, metatarsal III and pes phalanx III-2. The distal joint capsule of phalanx III-1 was also successful in protecting the distal end of the bone from the adjacent infection because the exostosis is not present on this portion of the phalanx.

There is also a pathologic allosaur pes phalanx III-1 (UUVP 1657, BYU; Figure 12) from the C-L collection. The proximal portion of the shaft is thickened by bone deposition, and the proximal joint surface is completely destroyed and remodeled into a sloping, irregular surface. The etiology of this pathologic element is tentatively identified by Petersen et al. (1972, p. 46): "Two possible causes of this condition are tuberculosis and trauma." Similarities between MOR 693's phalanx and UUVP 1657 are the increased diameter of the proximal shaft, presence of lesion(s) on the proximal surface, and unaffected distal joint. The main difference in morphology is the nature of the proximal articulation surface--that of MOR 693 is still well-defined, whereas on UUVP 1657 the surface is remodelled and sloping. Given its similar morphology to MOR 693's phalanx, UUVP 1657 was probably affected by osteomyelitis (and conceivably trauma if the

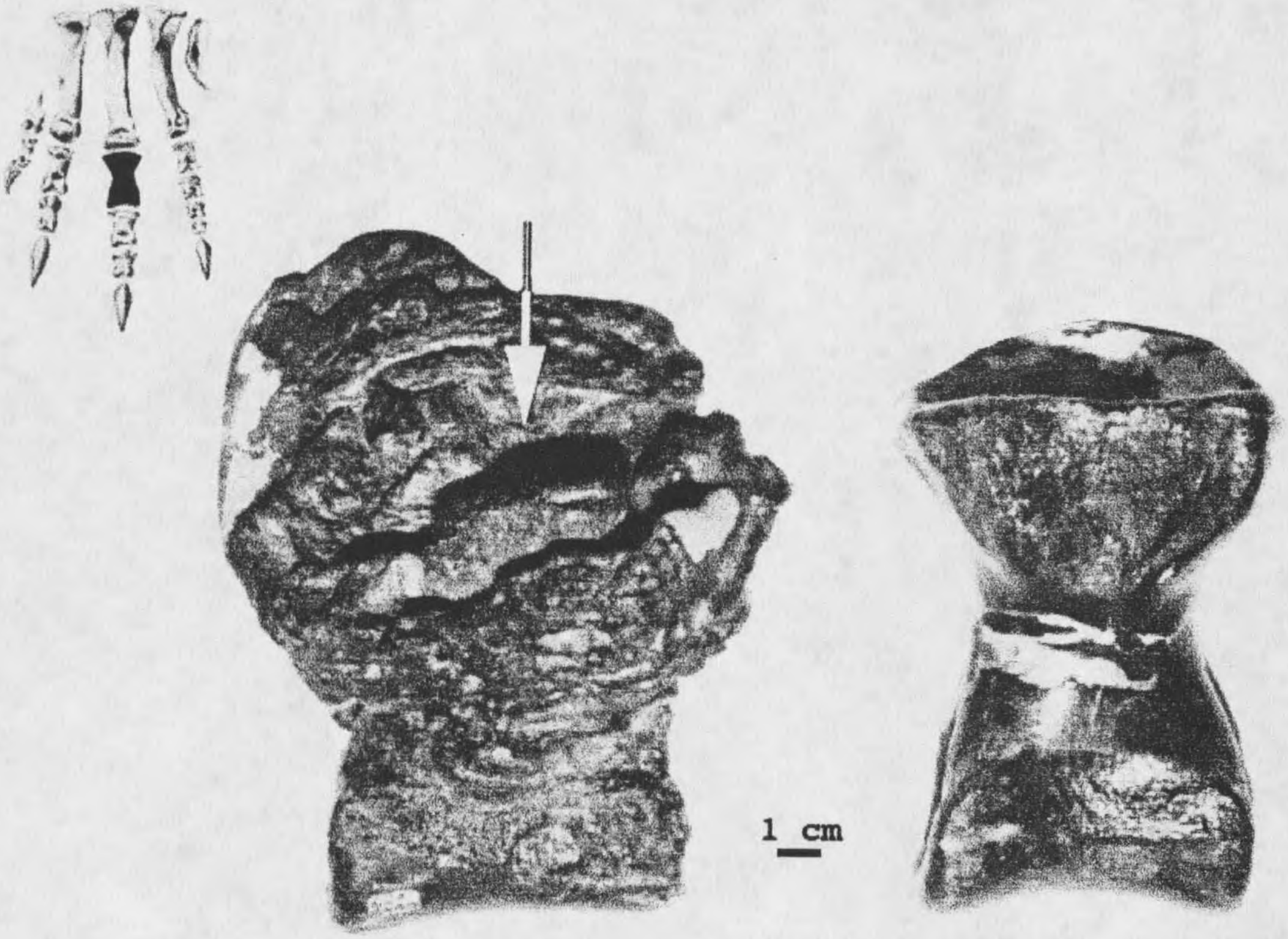

Figure 12: Inferior view of pathological left pes phalanx III-1 on left (UUVP 1657) and normal pes phalanx III-1 (UUVP 40-100) on right from the Cleveland-Lloyd dinosaur collection (BYU). Anterior view of allosaur foot (modified from Madsen, 1976) at upper left shows anatomical location of pathological phalanx. Scale applies to phalanges in foreground only. Note large exostosis surrounding the proximal portion of phalanx on left, and lesion on proximal articulation surface (arrow).

infection originated via an open fracture), rather than tuberculosis.

Other evidence of joint infection is present in the C-L collection on right metatarsal IV (UUVP 30-783, BYU), left pes phalanx III-1 (UUVP 6768, BYU), and left pes phalanx IV-1 (UUVP 1851, U of Utah). Both UUVP 30-783 and 1851 have lesions on their distal articulation surfaces caused by microbial entrance into the joint capsule (Swanson, pers. comm., 1995) between metatarsal IV and phalanx IV-1, and pes phalanges IV-1 and IV-2, respectively. A minor lesion due to microbial entrance between metatarsal III and phalanx III-1 is present on the proximal articulation surface of UUVP 6768.

Pes phalanx II-3

The offset of the medial groove on left pes phalanx II-3 is either an acute trauma-induced abnormality which resulted from direct violence to the digit II claw sheath and indirect violence to the ungal, or aberrant.

Evidence of ungal trauma has been observed in the C-L collection. A trauma-induced callus is present in inferior view on left pes phalanx II-3 (UUVP 1853, BYU), adjacent to the proximal articulation surface.

Metatarsals

Metatarsal III

The two minor bony spicules extending laterally from the diaphysis of left metatarsal III (Figure 13) are either trauma-induced sub-periosteal bone deposits or aberrant. Sub-periosteal bone forms when the periosteum is pulled away from the diaphysis activating osteoblastic bone deposition (Edeiken et al., 1966). The periosteum is a tissue covering the entire bone, except for the articulation surfaces, and serves as attachment for muscles, tendons, and ligaments. If direct violence to adjacent muscle and/or connective tissue is responsible for the bone production on the diaphysis, then the bony spicules are trauma-induced. Otherwise, the spicules are simply aberrant.

Metatarsal V

The exostosis on the lateral surface of right metatarsal V (Figure 14) is infection-induced, resulting from osteomyelitis. Osteomyelitis originates in bone marrow or through trauma, and would have progressed in the manner described for manus phalanx I-1. Microbes could have been introduced into adjacent tissue via a wound on the outside of the foot, causing exosteal growth on the lateral-most metatarsal.

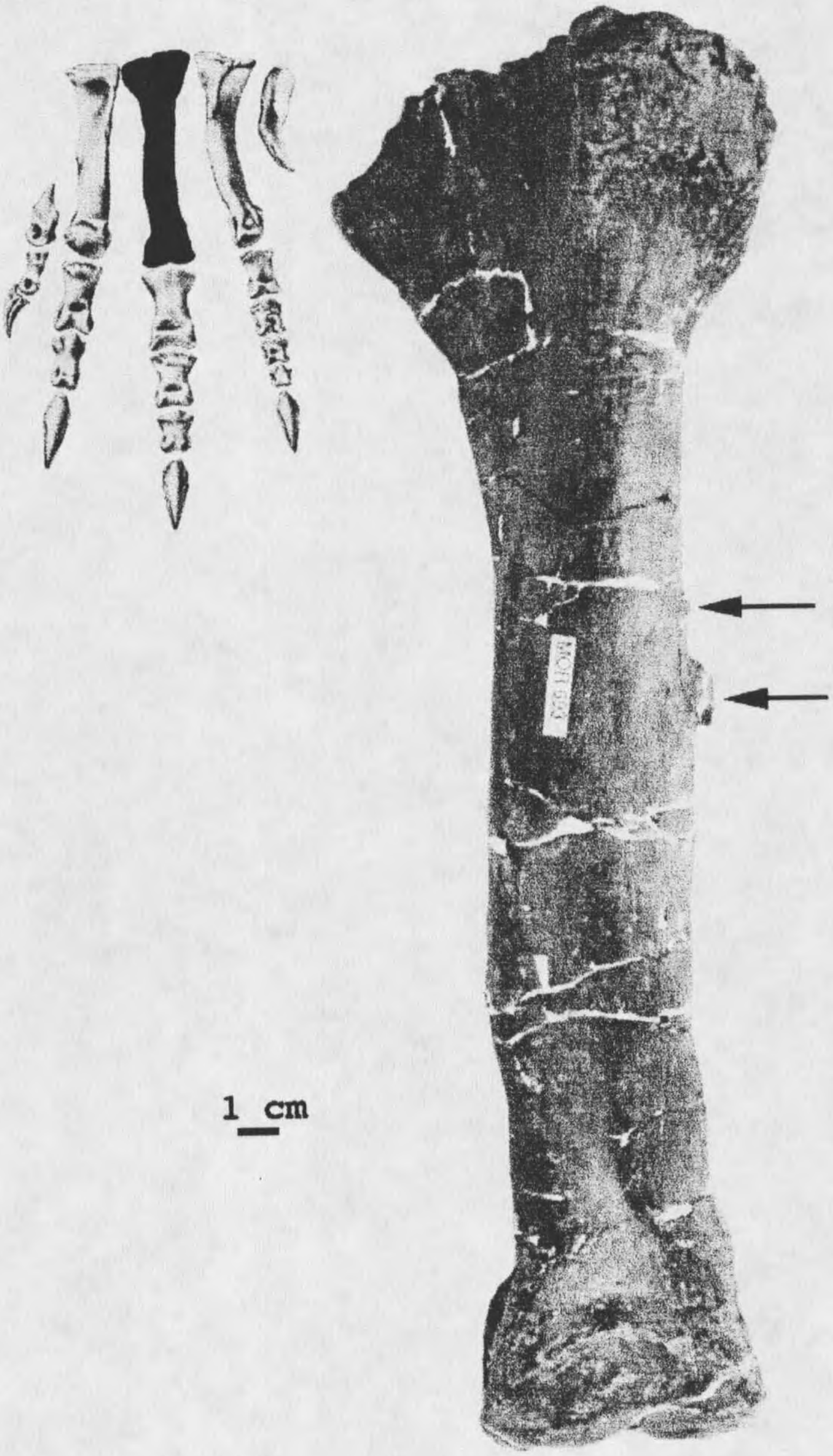

Figure 13: Anterior view of left metatarsal III showing bony spicules (arrows) projecting laterally from diaphysis. Anterior view of allosaur foot (modified from Madsen, 1976) at upper left shows anatomical location of metatarsal III. Scale applies to photograph only (Copyright Museum of the Rockies, Bruce Selyem photo).

Figure 14: Lateral view of right metatarsal V showing irregular, rugose exosteal growth covering the lateral surface (photo, Terry Panasuk; Copyright Museum of the Rockies). Anterior view of allosaur foot (modified from Madsen, 1976) at upper left shows anatomical location of metatarsal V (oriented in medial view). Scale applies to photograph only.

Illium

The origin of the aberrant thickening of the dorsal mid-illiac blade is unknown. Some event caused the bone to be thickened, but it is difficult to visualize a scenario which would have widened the bone so locally given the surrounding musculature and excellent blood supply of the illium (Wendt, pers. comm., 1996). If the thickening is trauma-induced, then the illium may have received an avulsion fracture, where a piece was pulled away from the main bone by the force of muscular contraction alone. However, an avulsion fracture probably would have affected a larger area and would not have been as localized.

Injury in the pelvic region is present in the C-L collection on an ischium (UUVP 3243, BYU) and an illium and ischium (UUVP 5985, BYU). The caudal extension of UUVP 3243 has a trauma-induced, healed, overlapping, slightly malaligned fracture with callus formation. On UUVP 5985, fusion of the illium and ischium occurred along the suture and is smooth on the medial surface but malaligned on the lateral surface. It may be possible that these elements fused with age, the fusion between these two being offset slightly.

DISCUSSION

Implications for MOR 693

How did each of the 19 abnormalities affect this subadult allosaur while it was alive? The broken ribs, gastralia, and chevron would have been severely painful, but not debilitating. The oblique-longitudinal fracture and osteomyelitis in phalanx I-1 of the right hand not only thickened the diameter of digit I, but would have caused pain during use. If the spicules of bone on the diaphysis of metatarsal III were the result of an acute trauma to the periosteum in which adjacent muscle or connective tissue was involved in the injury, then the allosaur's mobility would have been slightly inhibited during repair. Even though the claw groove on left pes ungal II-3 is offset, the claw on the second left toe would have still been functional. The hole on the scapula blade was a minor abnormality which, if trauma-induced, would have been accompanied by a painful flesh wound. However, if this was an aberrancy, then the allosaur's activity would not have been affected by its presence. Likewise, the exostosis on dorsal vertebra 3 and ossification within the interspinous ligaments of cervical vertebra 6, dorsal vertebrae 8 and 13, and caudal vertebra 2 had no effect on its mobility. Since the origin of the mid-illiac blade thickening is uncertain, the affect of this aberrancy on the allosaur was not determined. The exostosis on metatarsal V would have been accompanied by swelling and pain, as this bone is located on the outside of the foot. Also in the right foot is the osteomyelitic pes phalanx III-1. The exostosis around this bone would have enlarged the diameter of the toe, and with swelling may have caused the third toe to be in contact with toes II and IV. This affliction was probably the most painful to the allosaur, especially during locomotion since toe III is one of the three weight-bearing digits in the foot.

Implications for the species, *Allosaurus fragilis*

Evidence of infection and trauma is present in MOR 693 and the Cleveland-Lloyd collection. Theropod physiology, lifestyle, and behavior may have been responsible for the presence of pathology in *A. fragilis*.

Infection in the feet of allosaurs is noted by Petersen et al. (1972) and in this study. Since these dinosaur are carnivorous, they probably stood on rotting carcasses which were undoubtedly seething with microbes. It could be that some of the infections in the foot bones of these allosaurs were incurred while standing on carcasses, feeding. A wound or cut on the foot would have been a pathway for infection. Additionally, joints are good locations for microbial invasion (Swanson, pers. comm., 1995; Wendt, pers. comm., 1996).

Infections observed in pes phalanx III-1, metatarsal V, and manus phalanx I-1 of MOR 693, and two pes phalanges III-1 (UUVP 1657 and 6768), pes phalanx IV-1 (UUVP 1851), metatarsal IV (UUVP 30-783), and two scapula (UUVP 1528 and 5599) of the C-L collection are all localized, and some of them were even chronic. These pathologic bones demonstrate that allosaurs possessed an immune response which allowed them to live with microbial infection in their bones, probably by keeping it localized.

A preliminary survey conducted of the dinosaur remains in the Vertebrate Paleontology Collection at Museum of the Rockies led me to believe that pathologic bones were more frequent in carnivores than herbivores. Further examination of the frequency of pathologic dinosaur bones in other museum collections may confirm this hypothesis. Carnivores are able to live with injuries and infections longer than herbivores. A sick or injured herbivore is an easier target for a predator than a healthy herbivore, and therefore may not live with injuries/infections long enough for bone cells to record the malady. In contrast, due to its nature, a sick or injured carnivore is not as susceptible to as sudden a death. Additionally, because prey undoubtedly tried to defend themselves, trauma to the predator could have been incurred during interactions with its prey. It is unlikely for a herbivore to be injured by plants during foraging. Thus, the lifestyle of a carnivorous dinosaur probably predisposed it to injury.

Males are subjected to trauma during competition for mates and territory. The presence/absence of chevron 1 has been utilized for *Tyrannosaurus rex* to distinguish males from females (Larson, 1992). Chevron 1 was found in the tail section of "Big Al." Thus, if this character is truly an indicator of sex (and it is in modern alligators), then "Big Al" is a male allosaur. Skeletal dimensions show that this allosaur is a sub-adult. Using the allosaur growth series techniques (Bybee, 1996), it is estimated that this allosaur was 87% grown (Lamm, pers. comm., 1996). "Big Al" may have incurred some injuries during competition with other male allosaurs for carcasses, mates, and territory.

This study is a model for future paleopathological studies. The frequency of pathology varies significantly from one individual to the next (Ortner and Putschar, 1981; Mann and Murphy, 1990; Rothschild and Martin, 1993). Hence, the "[a]nalysis of pathology as a population phenomenon provides more insight than examination of isolated skeletons" (Rothschild and Martin, 1993). Comprehensive study of the frequency and anatomical distribution of pathologic bones seen within *A. fragilis* has not been done. A paleopathological analysis on a large sample of bones may reveal that certain abnormalities characterize taxa, and are diagnostic of specific behaviors, environmental influences, and physiology. Without this comparative database, the value of this analysis of the pathologic bones of MOR 693 is limited to an understanding of the individual's problems without relation to population phenomena. Hence, the significance of the allosaur's abnormalities will be better understood once a comprehensive paleopathological study of a large sample of allosaur bones is completed.

CONCLUSIONS

1) The lifestyle and behavior of a carnivorous dinosaur probably predisposed it to injury. "Big Al" is an 87% grown, sub-adult, male, *Allosaurus fragilis*, who may have incurred some injuries during competition with other males and pursuit of prey, and some infection while standing on carcasses, feeding.

2) Allosaurs possessed an immune response which allowed them to live with microbial infection in their bones, probably by keeping it localized.

3) A comprehensive analysis of a large sample of allosaur bones may reveal that certain abnormalities characterize *Allosaurus fragilis*, and are diagnostic of specific behaviors, environmental influences, and physiology. Hence, the significance of this sub-adult allosaur's 19 abnormal bones will be better understood once a comprehensive study of allosaur pathology is completed.

REFERENCES CITED

Bridge, J.S., 1985, Paleochannel patterns inferred from alluvial deposits: a critical evaluation: Journal of Sedimentary Petrology, v. 55, no. 4, p. 579-589.

Brown, B., 1935, Sinclair Dinosaur Expedition, 1934: Natural History, v. 36, p. 2-15.

Bybee, P.J., 1996, Histological bone structure differences in various sized elements from the Late Jurassic dinosaur *Allosaurus fragilis* of central Utah [Ph.D dissert.]: Provo, Utah, Brigham Young University, 200 p.

Chaplin, R.E., 1971, The study of animal bones from archaeological sites: New York, Seminar Press, 170 p.

Cooley, J.T., 1993, Fluvial systems in the Upper Jurassic Morrison Formation, northern Beartooth and Gallatin ranges: [M.S. thesis], Montana State University, Bozeman, Montana, 55 p.

Dodson, P., Behrensmeyer, A.K., Bakker, R.T., and McIntosh, J.S., 1980, Taphonomy and paleoecology of the dinosaur beds of the Jurassic Morrison Formation: Paleobiology, v. 6, no. 2, p. 208-232.

Edeiken, J., Hodes, P.J., and Caplan, L.H., 1966, New bone production and periosteal reaction: American Journal of Roentology, v. 97, no. 3, p. 708-718.

Elliot-Smith, G., 1908, The most ancient splints: British Medical Journal, v. 1, p. 732-734.

Fiorillo, A.R., 1994, Time resolution at Carnegie Quarry (Morrison Formation: Dinosaur National Monument, Utah): implications for dinosaur paleoecology: Contributions to Geology, University of Wyoming, v. 30, no. 2, p. 149-156.

Fiorillo, A.R., (in press), Bone modification features on sauropod remains (Dinosauria) from the Freezeout Hills Quarry N (Morrison Formation) of southeastern Wyoming and their contribution to fine-scale paleoenvironmental interpretation, *in* K. Carpenter, D. Chure, and J. Kirkland, eds., The Morrison Formation: Geological Society of America Special Paper, 26 p.

Friend, P.F., 1983, Toward the field classification of alluvial architecture or sequence, *in* J.D. Collinson and J. Lewin, eds., Modern and ancient fluvial systems: International Association of Sedimentologists Special Publication 6, p. 345-354.

Hrdlicka, A., 1914, Special notes on some of the pathological conditions shown by the skeletal material of ancient Peruvians: Smithsonian Miscellaneous Collections, v. 61, p. 57-69.

Jackson, R.G., II, 1976, Depositional model of point bars in the lower Wabash River: Journal of Sedimentary Petrology, v. 46, no. 3, p. 579-594.

Lamm, E., Museum of the Rockies histologist, personal communication on September, 6, 1996.

Larson, P.L., 1992, Sexual dimorphism in the abundant Upper Cretaceous theropod, *Tyrannosaurus rex*: Society of Vertebrate Paleontology, fifty-second annual meeting, v. 12, no. 3(suppl.), p. 38A.

Lawton, R., 1977, Taphonomy of the dinosaur quarry, Dinosaur National Monument: Contributions to Geology, University of Wyoming, v.. 15, no. 2, p. 119-126.

Madsen, J.H., 1976, *Allosaurus fragilis*: A revised osteology: Utah Geological & Mineral Survey, Bulletin 109, 163 p.

Mann, R.W., and Murphy, S.P., 1990, Regional atlas of bone disease: A guide to pathologic and normal variation in the human skeleton: Springfield, Illinois, Charles C. Thomas, 208 p.

Miall, A.D., 1978, Lithofacies types and vertical profile models in braided river deposits: a summary, *in* A.D. Miall, ed., Fluvial sedimentology: Canadian Society of Petroleum Geologists Memoir 5, p. 597-604.

Miall, A.D., 1985, Architectural-element analysis: a new method of facies analysis applied to fluvial deposits: Earth Science Reviews, v. 22, p. 261-308.

Moodie, R.L., 1916a, Two caudal vertebrae of a sauropodus dinosaur exhibiting a pathological lesion: American Journal of Science, v. 41, no. 4, p. 530-531

Moodie, R.L., 1916b, Mesozoic pathology and bacteriology: Science, v. 43, p. 425-426..

Moodie, R.L., 1917, The influence of disease in the extinction of races: Science, v. 45, p. 63-64.

Moodie, R.L., 1918a, Paleontological evidences of the antiquity of disease: Science Monthly, v. 7, p. 265-281.

Moodie, R.L., 1918b, Studies in paleopathology: III. Opisthotonus and allied phenomena among vertebrates: American Naturalist, v. 51, p. 617-618.

Moodie, R.L., 1918c, Synthesis of paleontology and medical history: Science, v. 48, p. 619-620.

Moodie, R.L., 1918d, Studies in Paleopathology: Pathological evidences of disease among ancient races of man and extinct animals: Surgery, Gynecology, and Obstetrics, v. 27, p. 498-510.

Moodie, R.L., 1918e, Studies in Paleopathology: I. General considerations of the evidences of pathological conditions found among fossil animals: Annals of Medical History, v. 1, no. 4, p. 374-393.

Moodie, R.L., 1921a, Osteomyelitis in the Permian: Science, v. 53, p. 33.

Moodie, R.L., 1921b, Status of our knowledge of Mesozoic pathology: Bulletin of the American Geological Society, v. 32, p. 321.

Moodie, R.L., 1922, The paleopathology of the parasuchians: Science, v. 56, p. 417.

Moodie, R.L., 1923a, Paleopathology: An introduction to the study of ancient evidence of disease: Urbana, Univ. of Illinois Press, 542 p.

Moodie, R.L., 1923b, An unusual form of Pliocene pathology: American Journal of Science, vol. 5, no. 5, p. 334-336.

Moodie, R.L., 1926a, Studies in Paleopathology: II. Excess callus following fracture of the fore foot in a Cretaceous dinosaur: Annals of Medical History, v. 8, p. 73-77.

Moodie, R.L., 1926b, Studies in Paleopathology: XIII. The elements of the Haversian system in normal and pathological structures among fossil vertebrates: Biologia Generalis, v. 2, p. 63-95.

Moodie, R.L., 1927a, Tumors in the Lower Carboniferous: Science, vol. 66, p. 540.

Moodie, R.L., 1927b, Studies in Paleopathology: XX. Vertebral lesions in the Sabre-tooth, Pleistocene of California, resembling the so-called Myositis Ossificans Progressiva, compared with certain ossification in the dinosaurs: Annals of Medical History, v. 9, p. 91-102.

Moodie, R.L., 1928, The histological nature of ossified tendons found in dinosaurs: American Museum Novitates, no. 311, p. 1-15.

Moodie, R.L., 1930, Dental abscesses in a dinosaur millions of years old, and the oldest yet known: Pacific Dental Gazette, v. 38, p. 435-440.

Nanson, G.C., and Page, K., 1983, Lateral accretion of fine-grained concave benches on meandering rivers, *in* J.D. Collinson and J. Lewin, eds., Modern and ancient fluvial systems: International Association of Sedimentologists Special Publication 6, p. 133-143.

Ortner, D.J., and Putschar, W.G.J., 1981, Identification of pathological conditions in human skeletal remains: Washington, D.C., Smithsonian Institution Press, 488 p.

Petersen, K., Isakon, J.I., and Madsen, J.H., Jr., 1972, Preliminary study of paleopathologies in the Cleveland-Lloyd dinosaur collection: Utah Academy Proceedings, v. 49, no. 1, p. 44-47.

Peterson, F. and Turner-Peterson, C.E., 1987, The Morrison Formation of the Colorado plateau: recent advances in sedimentology, stratigraphy, and paleotectonics: Hunteria, v. 2, no. 1, p. 1-17.

Rogers, R.R., 1994, Collecting taphonomic data from vertebrate localities, *in* P. Leiggi and P. May, eds., Vertebrate paleontological techniques volume 1: New York, New York, Cambridge University Press, p. 47-58.

Rothschild, B.M., and Martin, L.D., 1993, Paleopathology: Disease in the fossil record, Ann Arbor, CRC Press, 386 p.

Ruffer, M.A., 1910, Remarks on the histology and pathological anatomy of Egyptian mummies: Cairo Scientific Journal, v. 4, p. 1-5.

Shipman, P., 1981, Life history of a fossil: Cambridge, Massachusetts, Harvard University Press, 222 p.

Smith, D.K., 1996, Morphometric variation in *Allosaurus* [Ph.D. dissert.]: Provo, Utah, Brigham Young University, 370 p.

Smith, N.D., 1972, Flume experiments on the durability of mud clasts: Journal of Sedimentary Petrology, v. 42, no. 2, p. 378-383.

Swanson, G., 1995, Orthopedic surgeon, personal communication on July 27, 1995.

Swierc, J.E., and Johnson, G.D., 1996, A local chronostratigraphy for the Morrison Formation, Northeastern Bighorn basin, Wyoming *in* Wyoming Geological Society Guidebook: Wyoming Geological Association, 47th Annual Field Conference, Guidebook, p. 315-327.

Swinton, W.E., 1981, Sir Marc Armand Ruffer: one of the first paleopathologists: Canadian Medical Association Journal, v. 124, p. 1388-1392.

Turner, C.E. and Fishman, N.S., 1991, Jurassic Lake T'oo'dichi': a large alkaline, saline lake, Morrison Formation, eastern Colorado plateau: Geological Society of America Bulletin, v. 103, p. 538-558.

Wendt, P., Orthopedic surgeon, personal communication on September 20, 1996.

APPENDIX

APPENDIX: Location, extent, and texture of abnormal area on the nineteen bones from MOR 693. Abbreviations: anterior (ant.), distal (dist.), dorsal (d.), caudal (cl.), cervical (c.), irregular (I), lateral (lat.), manus (m.), medial (med.), pes (p.), phalanx (phal.), posterior (post.), proximal (prox.), rough (R), texture (Tx.), ventral (v.), and vertebra (vert.).

Element	Location	Extent	Tx.
d. rib 3	on shaft, 30 cm v. to tuberculum	callus is 6 cm long and 1.5-3 cm wide	R I
d. rib 4	on shaft, 30 cm v. to tuberculum	callus is 5-5.5 cm long and 1-3 cm wide	R I
d. rib 5	on shaft, 34 cm v. to tuberculum	callus is 11 cm long & 3-6 cm wide	S
d. rib 6	on shaft, 13 cm v. to tuberculum	bone spicule is 6.5 cm long with dist. 2.4 cm projected	S
d. rib 14	on shaft, 13 cm v. to tuberculum	d. spicule projects 6 mm to the post.; v. spicule projects 3.5 mm ant. & med.	S
c. vert. 6	located on neural spine, from 1-3 cm & 3.5-5 cm dist. to d. edge, projecting to post.	d. exostosis covers width of neural spine & was 2 cm (d.-v.), 1-2cm (ant.-post.), & 1.3 cm wide; v. exostosis on right portion of spine is 1.5 cm (d.-v.), 0.5-1.5 cm (ant.-post.), & 0.5 cm (med.-lat.)	R I

d. vert. 3	on ant. left side of centrum	exostosis is 3 cm (d.-v.) by 3.5 cm (ant.-post.) & covers v. half of the left capitular surface, extending v. from facet	R
d. vert. 8	located on neural spine starting 2 cm dist. to d. edge, extending 6 cm v.; concentrated on right half of spine; projecting to post.	exostosis is 4 cm (d.-v.), 2-5 cm (ant.-post.), & 1-2 cm (med.-lat.)	R I
d. vert. 13	located on neural spine starting 2 cm dist. to the d. edge & extending 9 cm v.; projected to ant.	exostosis is 7 cm (d.-v.), 1-2.5 cm (ant.-post.), & 1.5-3 cm wide	R I
cl. vert. 2	located on neural spine starting 7.5 cm dist. to d. edge & extending 13 cm v. from zygopophyses; projected to post.	exostosis is 5.5 cm (d.-v.), 1.5-4.5 cm (ant.-post.), & 3-4.5 cm wide	R I
chevron 2	on left side of shaft, 8 cm from prox. articular surface	callus is 3 cm (d.-v.) by 1 cm (cranial-cl.)	S
gastralia 5	on shaft, 7 cm dist. to prox. (med.) articular surface	callus is 1.2 cm (med.-lat.) by 1.75 cm (ant.-post.)	R
scapula	on lat.-d. blade, 9 cm d. to post. edge of glenoid fossa	hole is 1.2 cm (d.-v.) by 0.85 cm (ant.-post.), & deepened from 0.1 cm to 0.8 cm (post.-ant.)	R I

m. phal. I-1	on shaft and dist. articular surface	exostosis (8 cm long & 0.7 cm wide) surrounds the entire shaft, with some bone growth present on the dist. articular surface	R I
p. phal. III-1	majority of prox. shaft; prox. articular surface	exostosis surrounds prox. half increasing width to 12 cm at prox. end (normal left p phal III-1 = 6.1 cm) and 8 cm at central shaft (normal was 3.9 cm); lesion on prox. surface is 4.4 cm (med.-lat.) by 2 cm (ant.-post.) & ranges from 1-2 cm deep	R I
p. phal. II-3 (ungal)	1.5 cm prox. to dist. tip, inferior to but encroachng upon claw groove	exostosis is 1.3 cm (prox.-dist.) & 1.1 cm (med.-lat.); depth of claw groove decreases from 2 to 1 mm	S
metatarsal III	1 prox. & 1 dist. spicule projected laterally from shaft 12.5 cm & 14.5 cm, respectively, dist. to prox. articular surface	prox. spicule is 7 mm (prox.-dist.) & 2 mm (med.-lat.); dist. spicule is 16 mm (prox.-dist.) & 5 mm (med.-lat.)	S

metatarsal V	entire lat. surface covered; intermittently present on ant., post., and med. surfaces	exostosis covers almost entire length of bone (12 cm) on lat. surface, causing thickness to be 2-3 cm in comparison to the normal thickness of 1-1.5 cm in left foot	R I
illium	on the d.-most portion of the mid-illiac blade, directly d. to the ischiac peduncle	thickened area extends 10 cm (ant.-post.) & at its thickest is 4.1 cm (compared to 2.1 cm on normal right illium); abscess within thickened area present in med. view	R I

PLATE 1

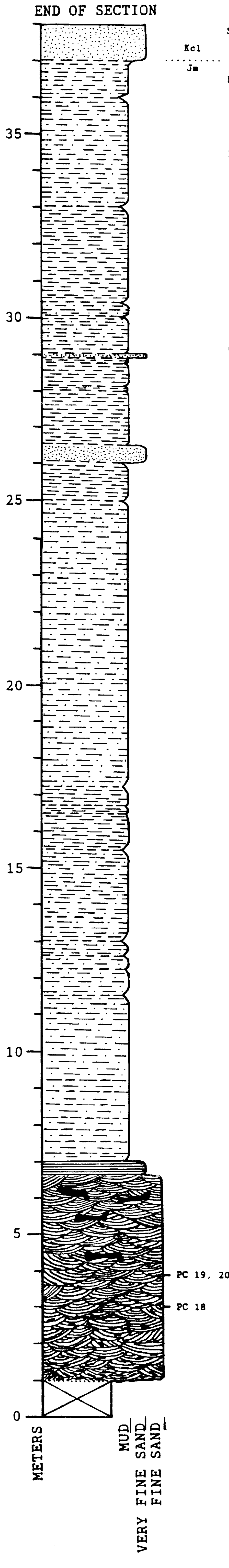

Sublitharenite; salmon weathering, pinkish-red, very fine-grained, subrounded, well sorted, non-calcareous

Mudstone; dark brown weathering, brownish-black

Mudstone; brown weathering, light brown, non-calcareous

Claystone; light pink weathering, dark brown, non-calcareous

Mudstone, dark pink weathering, light green and brown mottled

Mudstone; brown weathering, brown

Quartzarenite; yellow, very fine-grained, well sorted, subrounded, non-calcareous

Claystone; red and green

Claystone; light pink weathering, bright olive green

Claystone; olive green and pinkish-red, mottled, non-calcareous

Claystone; light tan weathering, olive green

Quartzarenite; white weathering, yellow, very fine-grained, well sorted, subrounded, non-calcareous

Claystone; light tan weathering, dark brown

Siltstone; light green to light tan weathering, greenish-brown

Claystone; light brown weathering, brown, calcareous

Claystone; brown weathering, brownish-red and bright green, mottled, calcareous

Claystone; dark red weathering, red, with occasional green mottling

Siltstone; reddish-brown weathering, green and dark red, mottled

Mudstone; brown weathering, bright green

Siltstone; dark red weathering, dark maroon

Siltstone; red weathering, green and red, mottled, calcareous

Siltstone; dark green, calcareous

grading into...

Mudstone; green weathering, dark green, calcareous

Quartzarenite; brown weathering, light tan, fine- to very fine-grained, well sorted, rounded, calcareous

Quartzarenite; orange weathering, light tan, fine-grained, well sorted, subrounded, calcareous

Covered

Measured section 1, for location see Fig. 4. Abbreviations: Jm, Jurassic Morrison Formation; Kcl, Cretaceous Cloverly Formation; PC, paleocurrent measurements.

KEY

Stratigraphic Contacts

——— sharp
- - - - gradational
∿∿∿ erosional
······ uncertain

Symbols

░ sandstone
▤ siltstone
▤ mudstone
▤ claystone
▩ trough cross-bedded sandstone
▤ horizontally stratified sandstone
☒ vegetative cover over outcrop
▬ dinosaur bones
≋ carbonized plant material

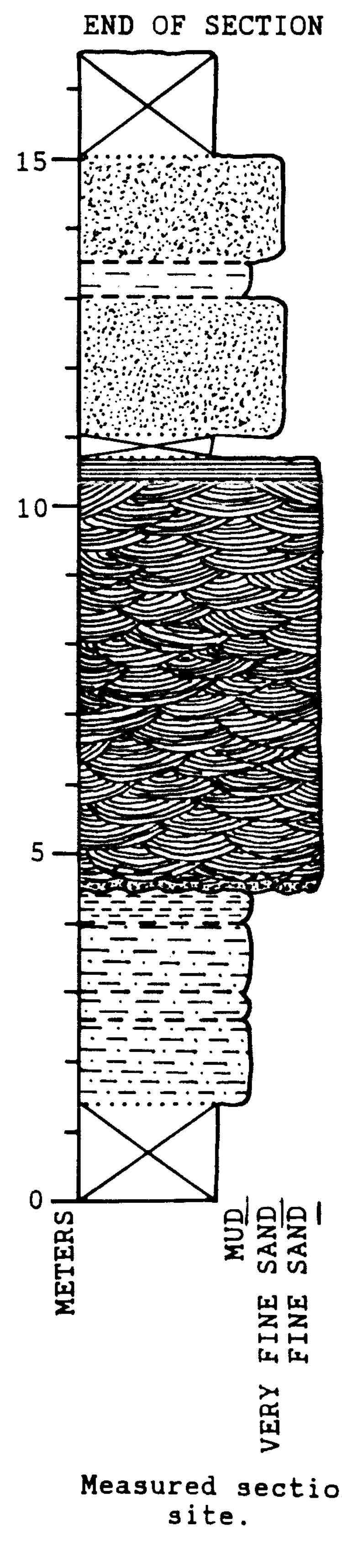

Covered

Quartzarenite; light tan weathering, light tan, very fine-grained, subrounded, well sorted

Siltstone; green weathering, dark green

Quartzarenite; white weathering, white, very fine-grained, subrounded, well sorted, calcareous

Covered

Quartzarenite; yellow weathering, white, fine-grained, subrounded, calcareous--basal meter of unit contains green siltstone mud chips

Claystone; yellowish-green, calcareous

Siltstone; dark green, calcareous, with some iron staining

Siltstone; dark green, calcareous, with some purplish-red mottling

Siltstone; light green, calcareous

Covered

Measured section 2, located 100 meters northeast of the "Big Al" site.